

*Innovation to Breast Cancer Detection:  
A Study of Adjunct  
SoftVue™ Automated Whole Breast Ultrasound Tomography (SV)  
to Digital Mammography  
on Enhancing Lesion Localization and Characterization*

Yulei Jiang, Ph.D., Mary Yamashita, M.D., Jeremiah Perez, Ph.D.,  
Alexandra Edwards, M.A., Linda Larsen, M.D.,  
Elizabeth Kane, Ph.D., and John Papaioannou, M.S.



## Disclosures

- Delphinus Med. Tech. (DMT), sponsor
- Univ. of Chicago, reader study (grant, consulting fee, travel)
- M Yamashita, reader training (consulting fee)
- Avania, statistical analysis
  
- Y Jiang, consultant, QT

# Background: Breast Cancer Screening in Dense Tissue

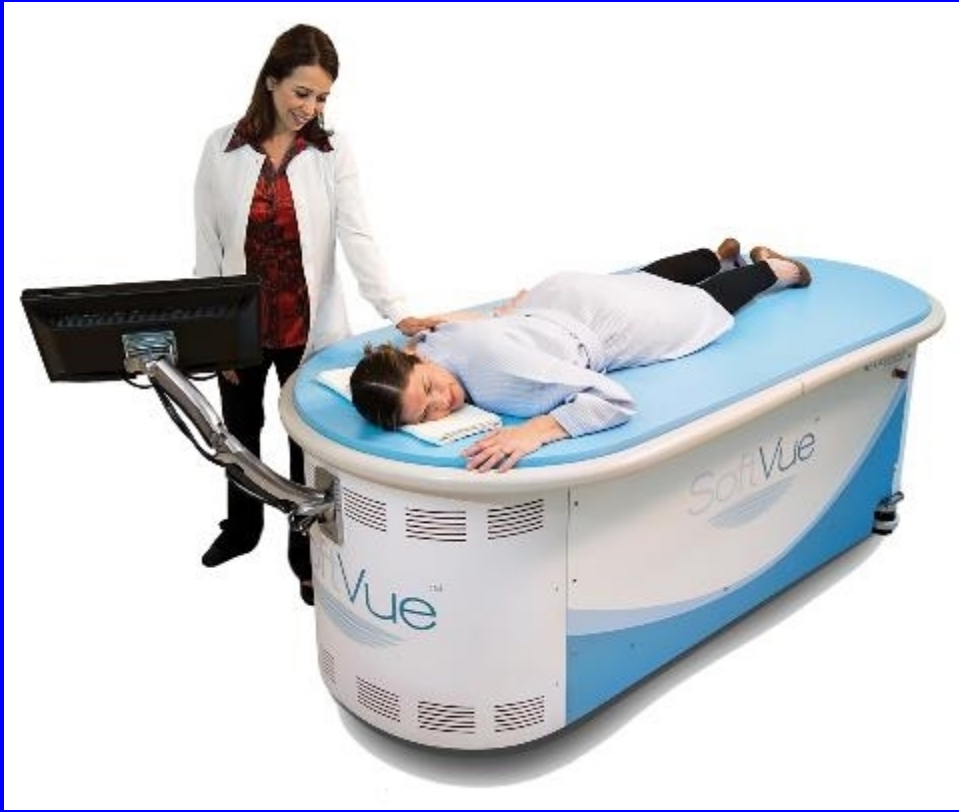- Dense breasts can mask cancer on mammography
- Increasing breast density is associated with an increased risk of breast cancer
  - 4.64-fold (3.64-5.91) for extremely dense compared with fatty

Boyd NF, Guo H, Martin LJ, Sun L, Stone J, Fishell E, Jong RA, Hislop G, Chiarelli A, Minkin S, Yaffe MJ. Mammographic density and the risk and detection of breast cancer. *N Engl J Med*. 2007 Jan 18;356(3):227-36. doi: 10.1056/NEJMoa062790. PMID: 17229950

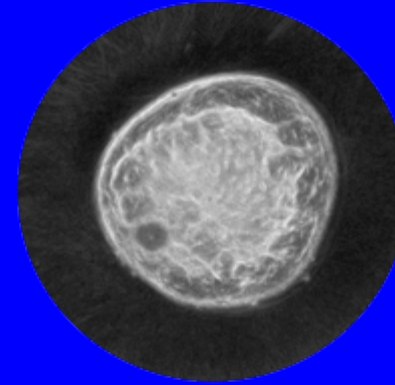
# Background: Breast Cancer Screening in Dense Tissue

- Adding ultrasound to mammography increases cancer detection:
- Limitations of handheld ultrasound
  - Shortage of trained technologists
  - Small field of view
  - Operator dependence
  - Increase in false positives; Reduced specificity
  - Increased recall rates; High rate of unnecessary biopsies
- Limitations of automated ultrasound
  - Several thousand images to review
  - Long interpretation time
  - False positives
  - Learning curve

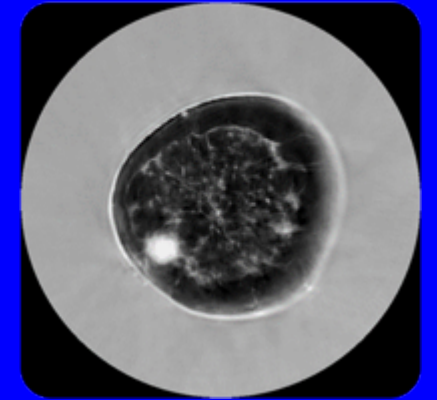
# SoftVue by Delphinus



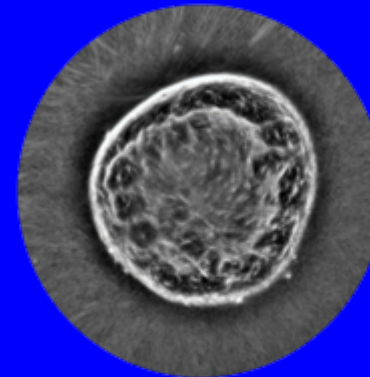
**Wafer  
(fat suppressed reflection)**



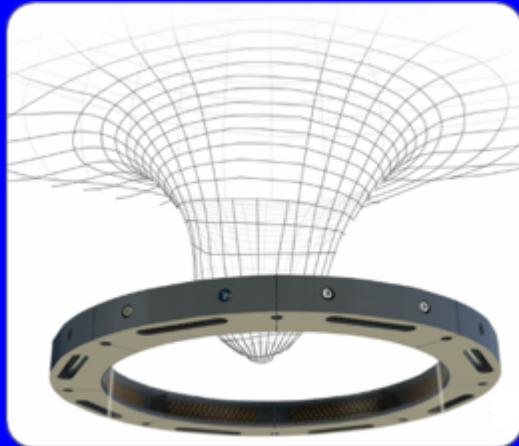
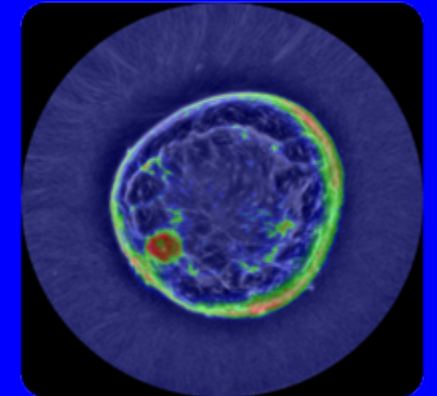
**Sound Speed**

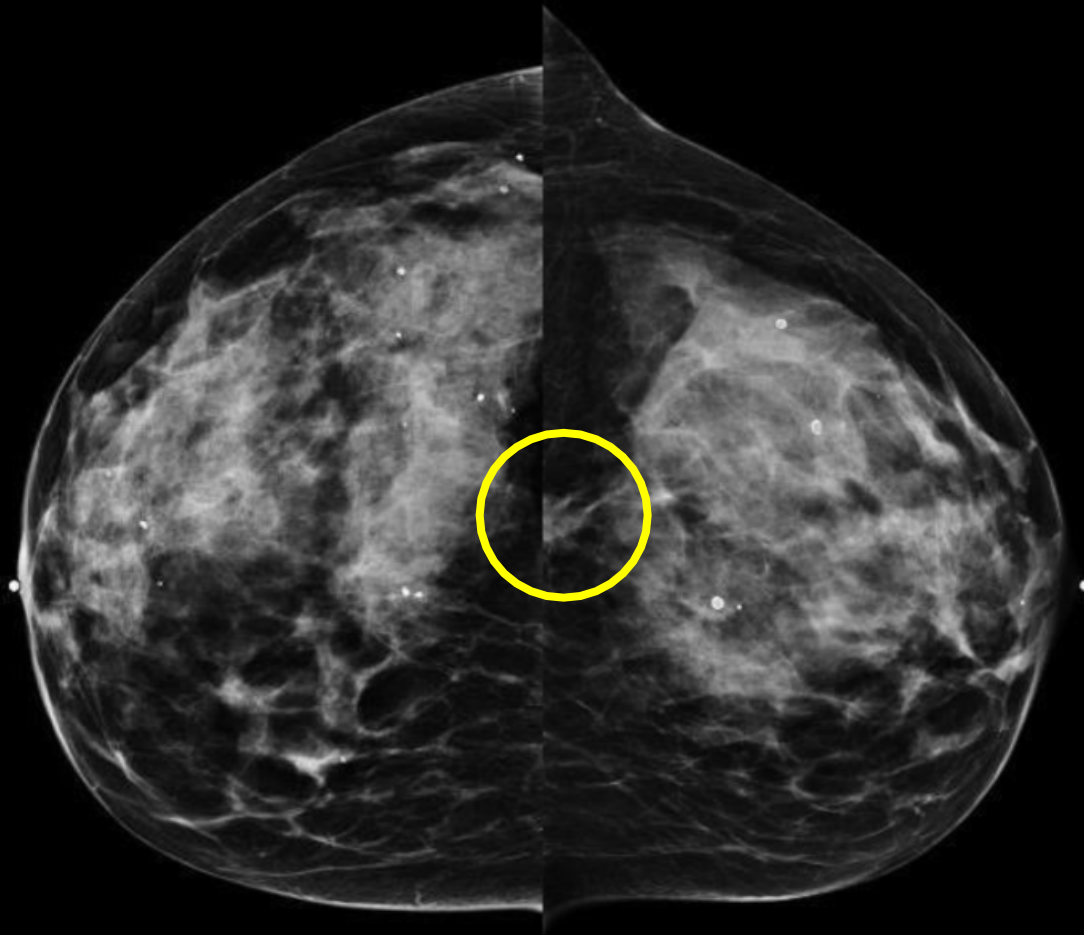
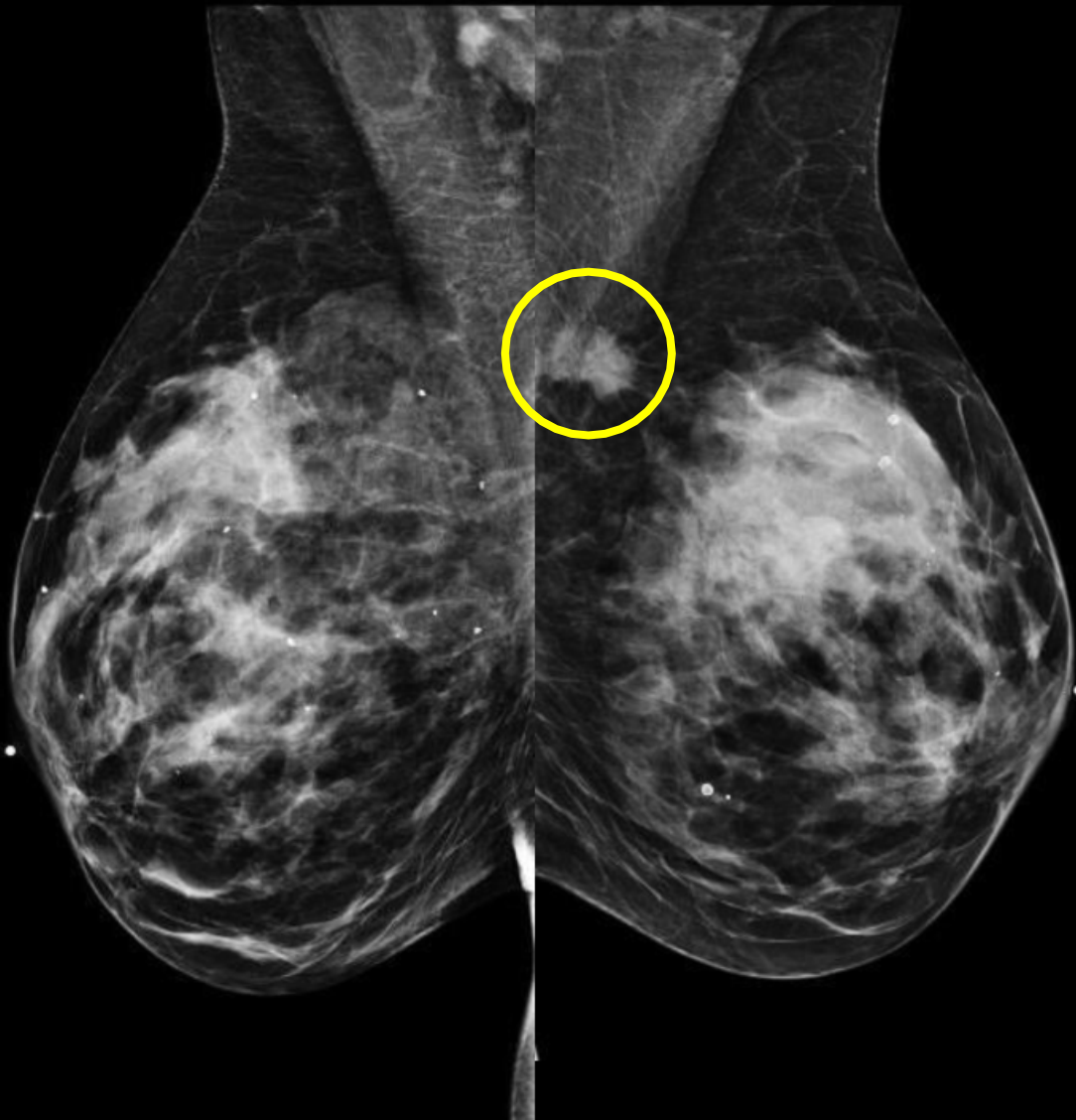


**Reflection  
(B-mode)**

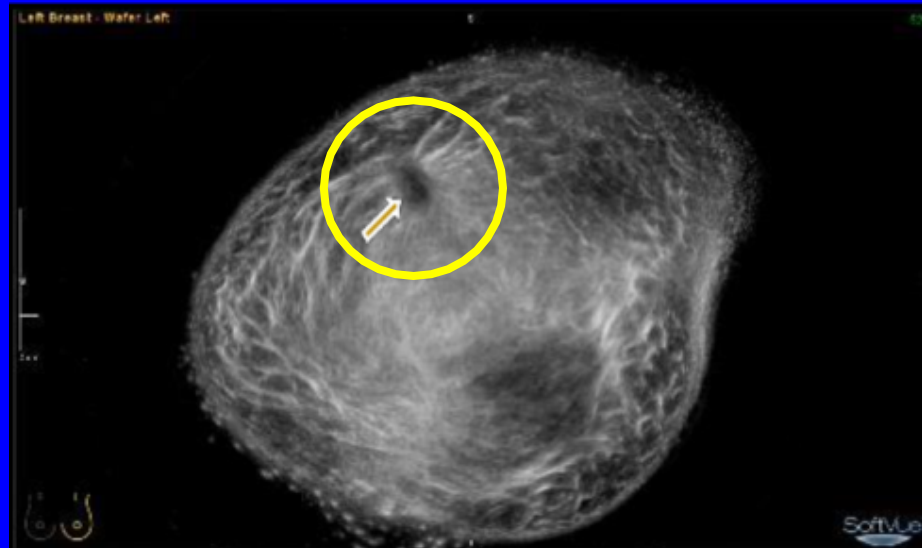


**Stiffness Fusion**

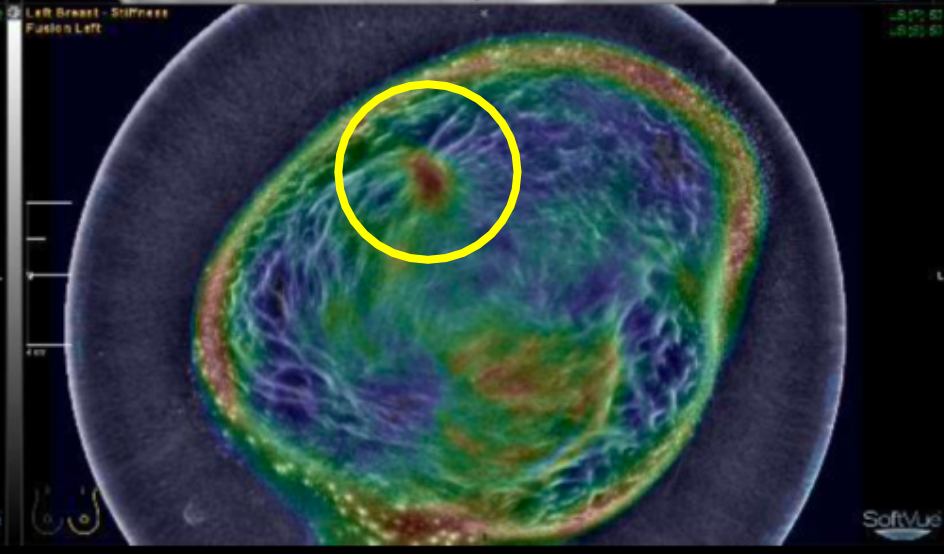
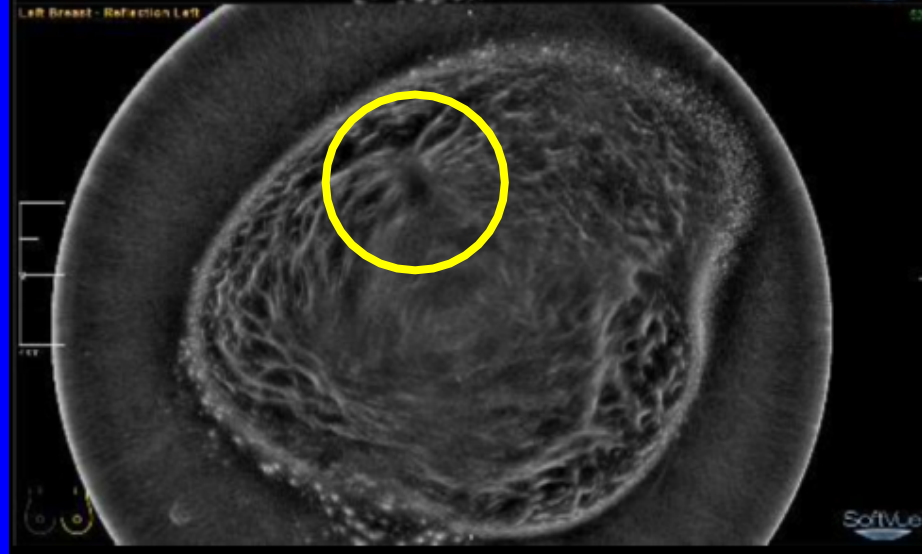
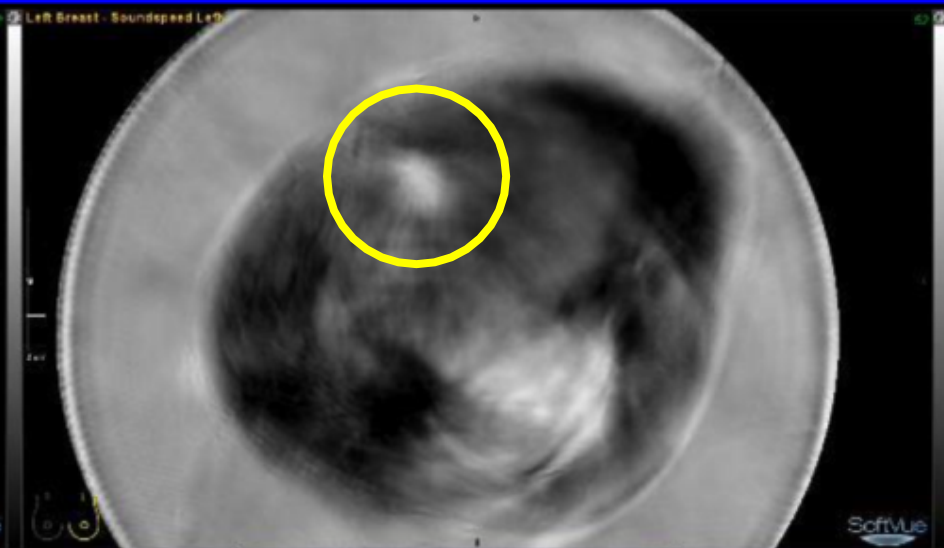




**Wafer  
(fat suppressed reflection)**



**Sound Speed**



**Reflection (B-mode)**

**Stiffness Fusion**

# Purpose and Study Endpoint

- Test hypothesis for breast cancer screening
  - FFDM + SoftVue better than FFDM alone
- Multi-reader multi-case (MRMC) reader study
  - Primary endpoint
    - Area under the ROC curve (AUC)
  - Secondary endpoints
    - Sensitivity (superiority test)
    - Specificity (non-inferiority test)



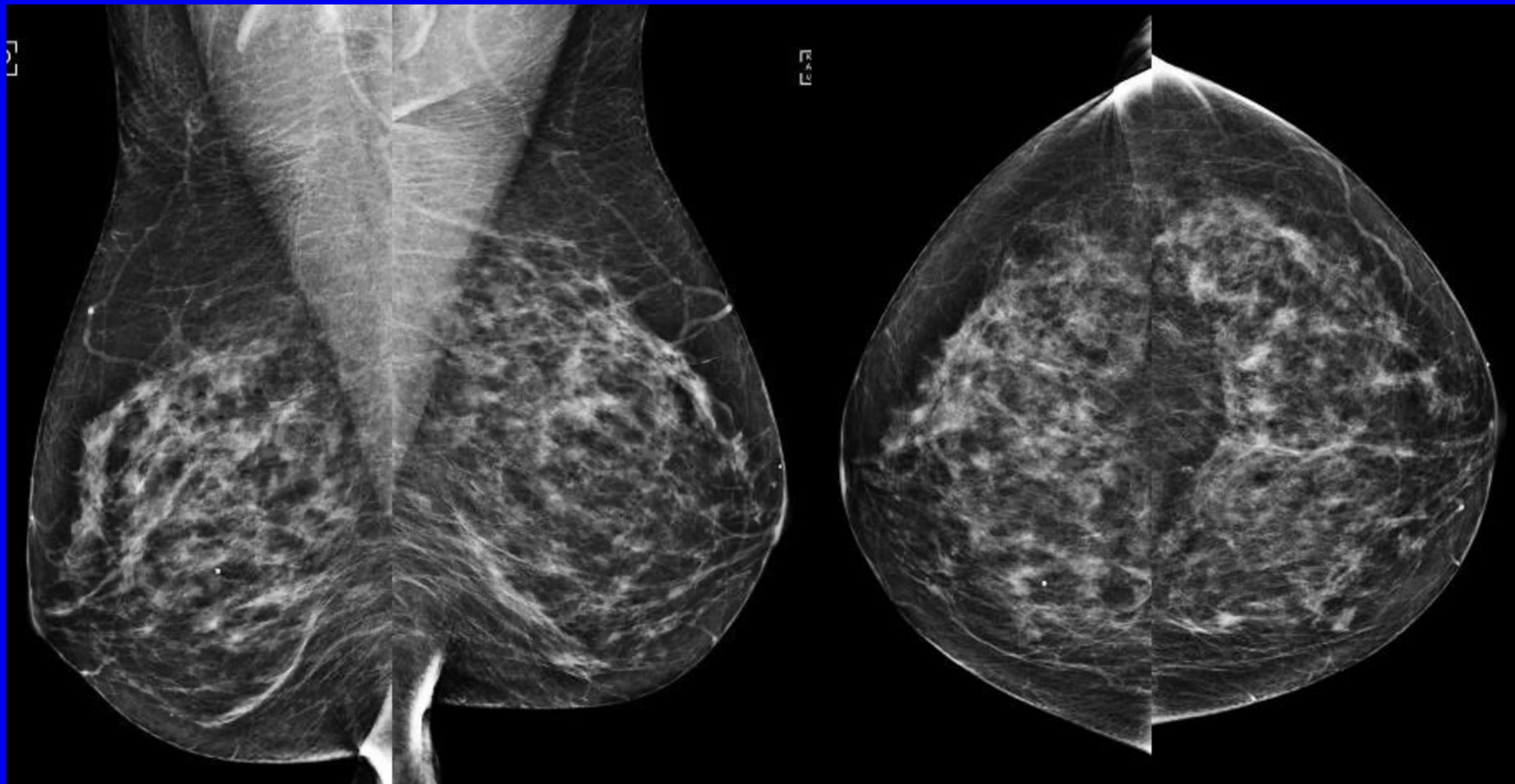
## Cases and Readers

- 140 cases (36 cancers, 104 random-sample non-cancers)
  - 4-view screening FFDM
  - All BI-RADS density c or d
  - All patients had SoftVue scans
- 32 MQSA-qualified radiologists from the United States
  - Academic, private, community
  - Breast imaging experience 2–37 years
  - Mammograms/Year median 5900 (range 500–25k)
  - Geographically diverse

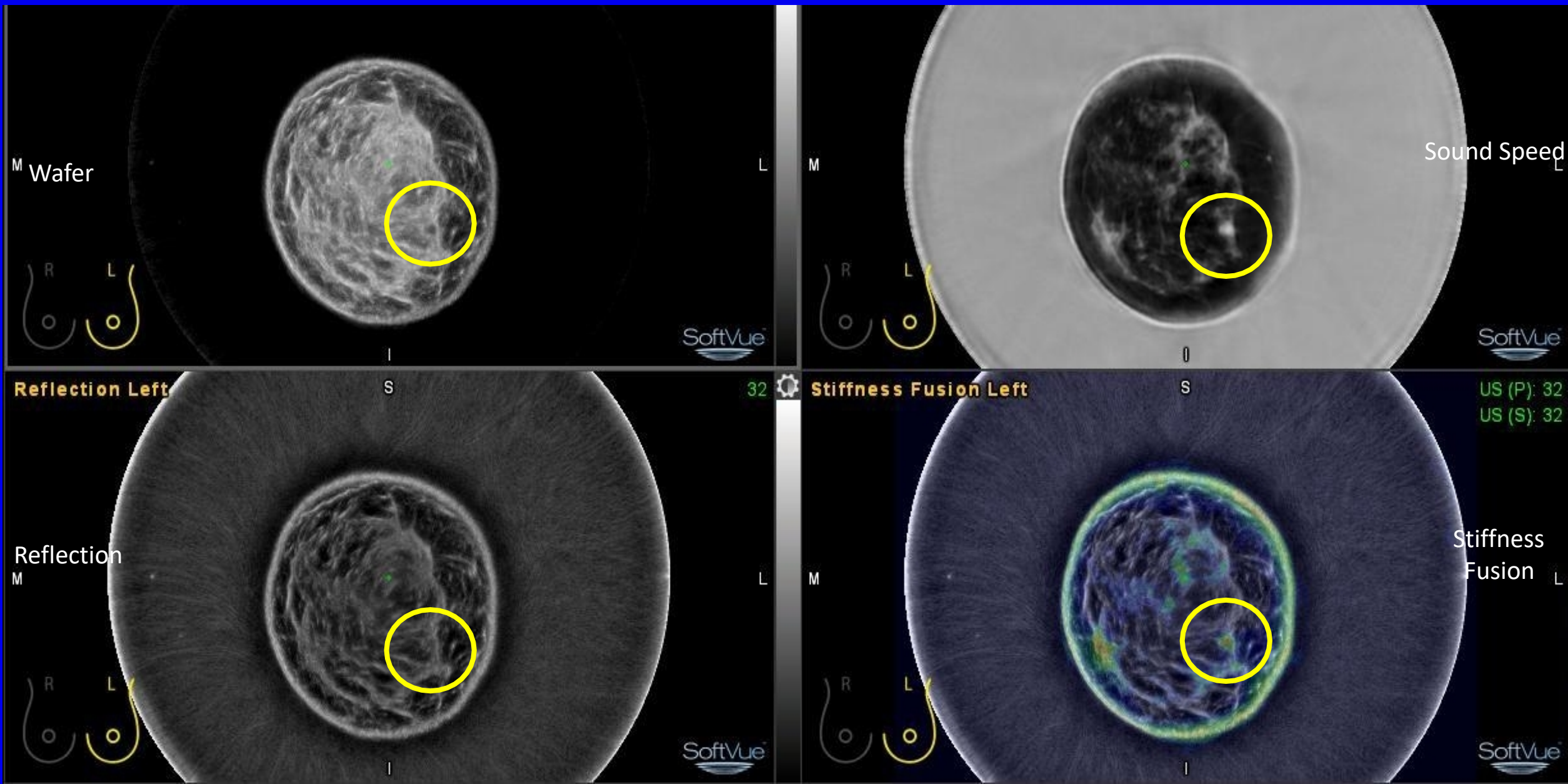
# Study Design

- Read cases individually in randomized order
- No more than 3 findings per case
- Malignancy score (0–100) — ROC analysis
- BI-RADS assessment (1–5) — sensitivity, specificity

# Reader Workflow: 4 views of FFDM

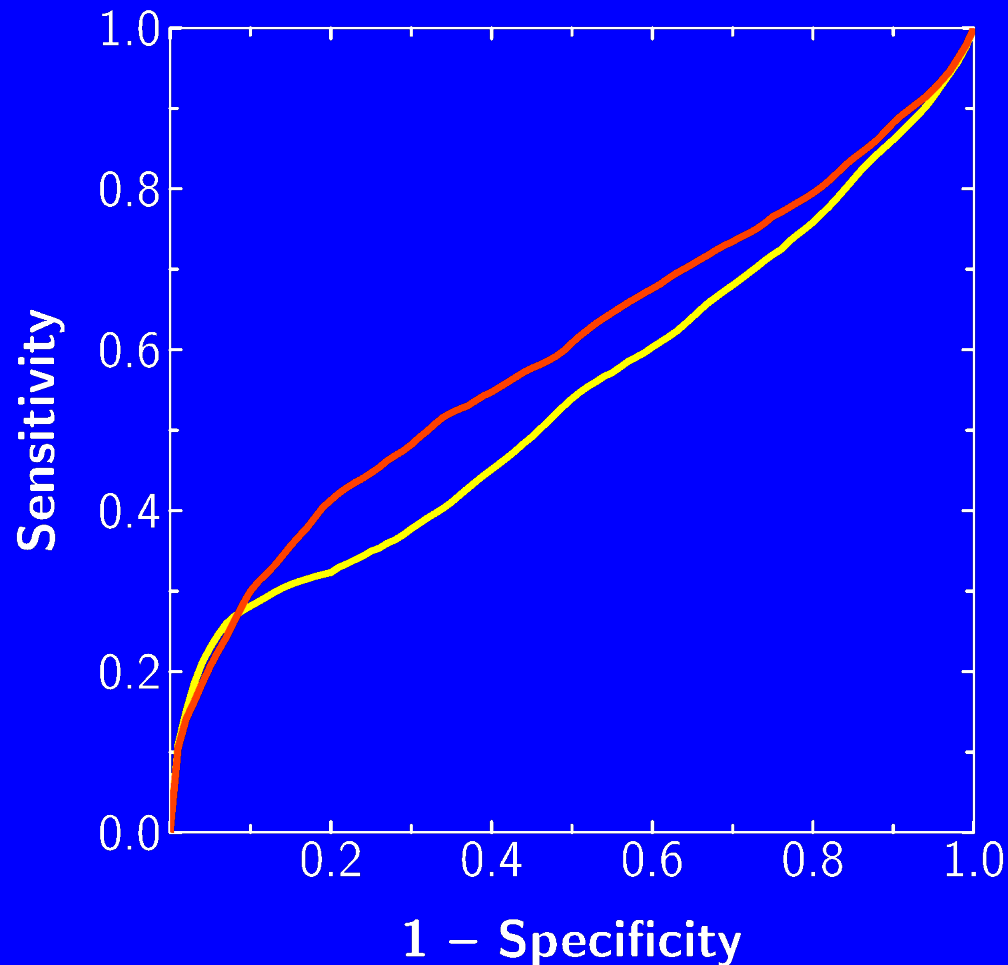


# Reader Workflow: 4 Sequences of SoftVue



# ROC Results

32 Readers, 140 Cases, Lesion Localization (15-mm)

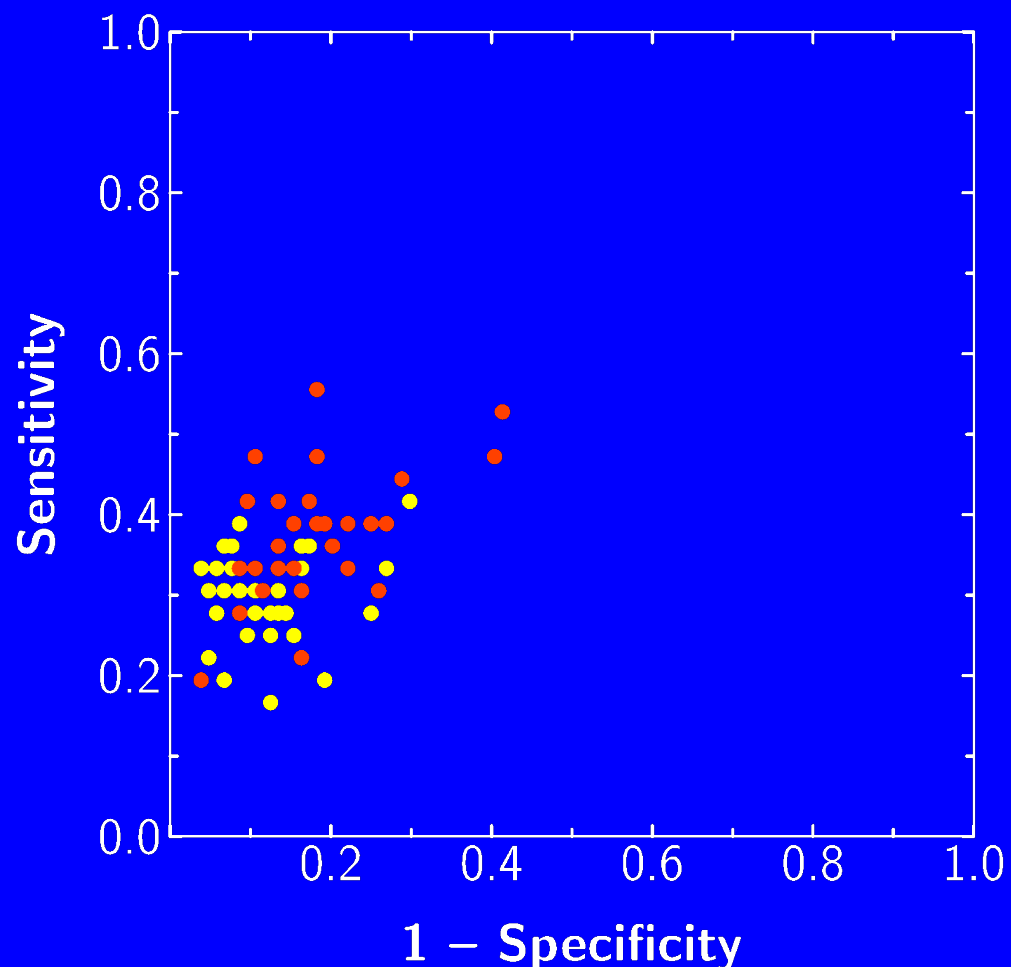


	AUC
<b>FFDM</b>	<b>0.54 ± 0.05</b>
<b>FFDM + SoftVue</b>	<b>0.60 ± 0.05</b>
<b>95% CI of <math>\Delta</math></b>	<b>(0.006, 0.103)</b>
<b>p-value</b>	<b>0.03</b>
<b>Stat. Sig.</b>	<b>*</b>
<b>Null Hypothesis</b>	<b><math>\Delta = 0</math></b>

MRMC statistical analysis allows for generalization of readers and cases

# Sensitivity, Specificity: Biopsy

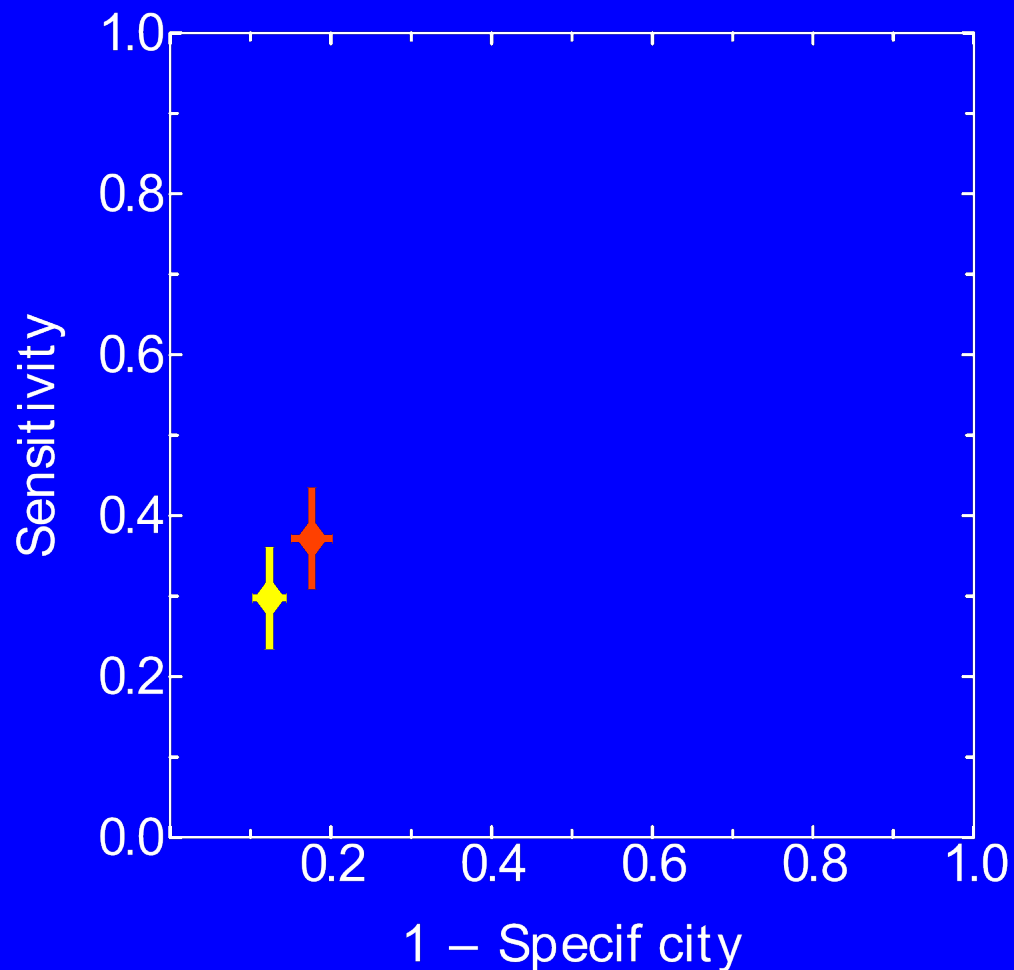
32 Readers, 140 Cases, Lesion Localization (15-mm)



	Sensitivity	1-Specificity
<b>FFDM</b>	<b>30 ± 6%</b>	<b>12 ± 2%</b>
<b>FFDM+SoftVue</b>	<b>37 ± 6%</b>	<b>18 ± 3%</b>
<b>95% CI of <math>\Delta</math></b>	<b>(0.7%, 14%)</b>	<b>(2%, 9%)</b>
<b>p-value</b>	<b>0.03</b>	<b>0.004</b>
<b>Stat. Sig.</b>	<b>*</b>	<b>*</b>
<b>Null Hypothesis</b>	<b><math>\Delta = 0\%</math></b>	<b><math>\Delta &gt; 10\%</math></b>

# Sensitivity, Specificity: Biopsy

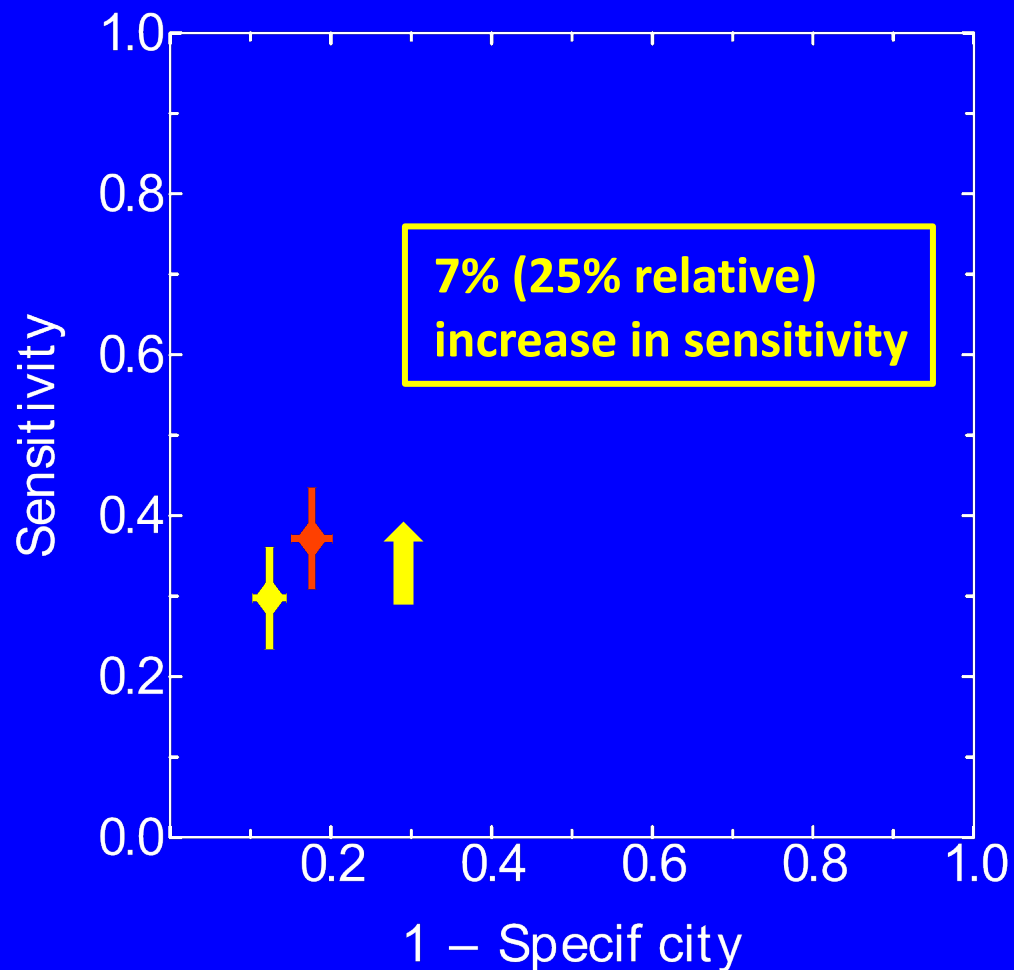
32 Readers, 140 Cases, Lesion Localization (15-mm)



	Sensitivity	1-Specificity
<b>FFDM</b>	<b>30 ± 6%</b>	<b>12 ± 2%</b>
<b>FFDM+SoftVue</b>	<b>37 ± 6%</b>	<b>18 ± 3%</b>
<b>95% CI of <math>\Delta</math></b>	<b>(0.7%, 14%)</b>	<b>(2%, 9%)</b>
<b>p-value</b>	<b>0.03</b>	<b>0.004</b>
<b>Stat. Sig.</b>	<b>*</b>	<b>*</b>
<b>Null Hypothesis</b>	<b><math>\Delta = 0\%</math></b>	<b><math>\Delta &gt; 10\%</math></b>

# Sensitivity, Specificity: Biopsy

32 Readers, 140 Cases, Lesion Localization (15-mm)

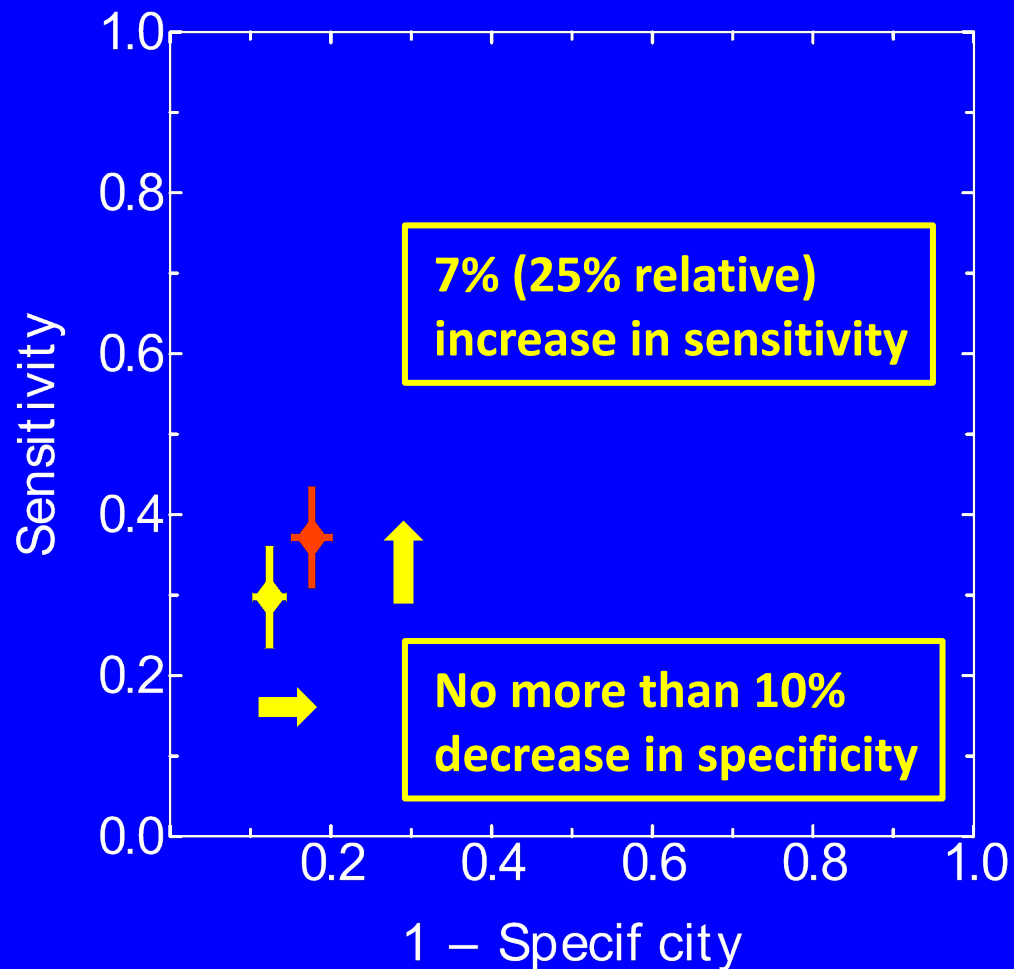


	Sensitivity	1-Specificity
<b>FFDM</b>	<b>30 ± 6%</b>	<b>12 ± 2%</b>
<b>FFDM+SoftVue</b>	<b>37 ± 6%</b>	<b>18 ± 3%</b>
<b>95% CI of <math>\Delta</math></b>	<b>(0.7%, 14%)</b>	<b>(2%, 9%)</b>
<b>p-value</b>	<b>0.03</b>	<b>0.004</b>
<b>Stat. Sig.</b>	<b>*</b>	<b>*</b>
<b>Null Hypothesis</b>	<b><math>\Delta = 0\%</math></b>	<b><math>\Delta &gt; 10\%</math></b>



# Sensitivity, Specificity: Biopsy

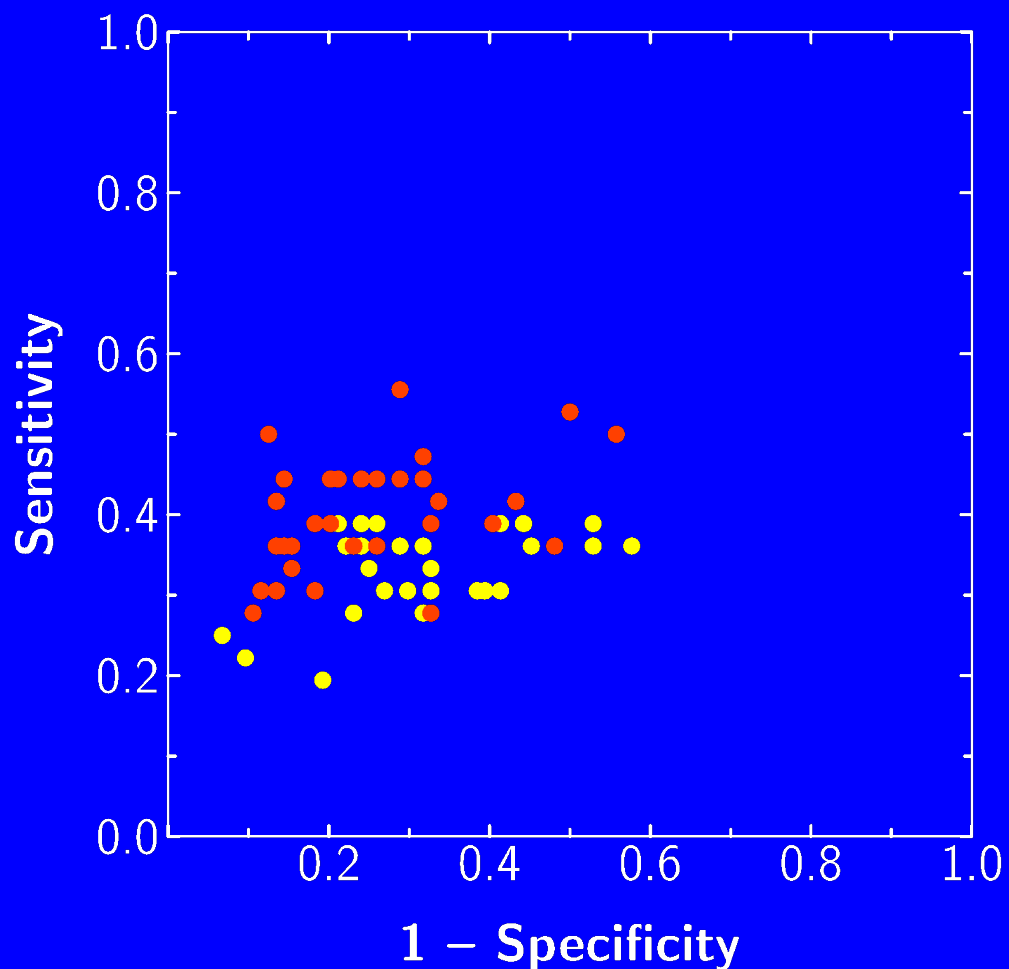
32 Readers, 140 Cases, Lesion Localization (15-mm)



	Sensitivity	1-Specificity
<b>FFDM</b>	<b>30 ± 6%</b>	<b>12 ± 2%</b>
<b>FFDM+SoftVue</b>	<b>37 ± 6%</b>	<b>18 ± 3%</b>
<b>95% CI of <math>\Delta</math></b>	<b>(0.7%, 14%)</b>	<b>(2%, 9%)</b>
<b>p-value</b>	<b>0.03</b>	<b>0.004</b>
<b>Stat. Sig.</b>	<b>*</b>	<b>*</b>
<b>Null Hypothesis</b>	<b><math>\Delta = 0\%</math></b>	<b><math>\Delta &gt; 10\%</math></b>

# Sensitivity, Specificity: Short-term Follow-up or Biopsy

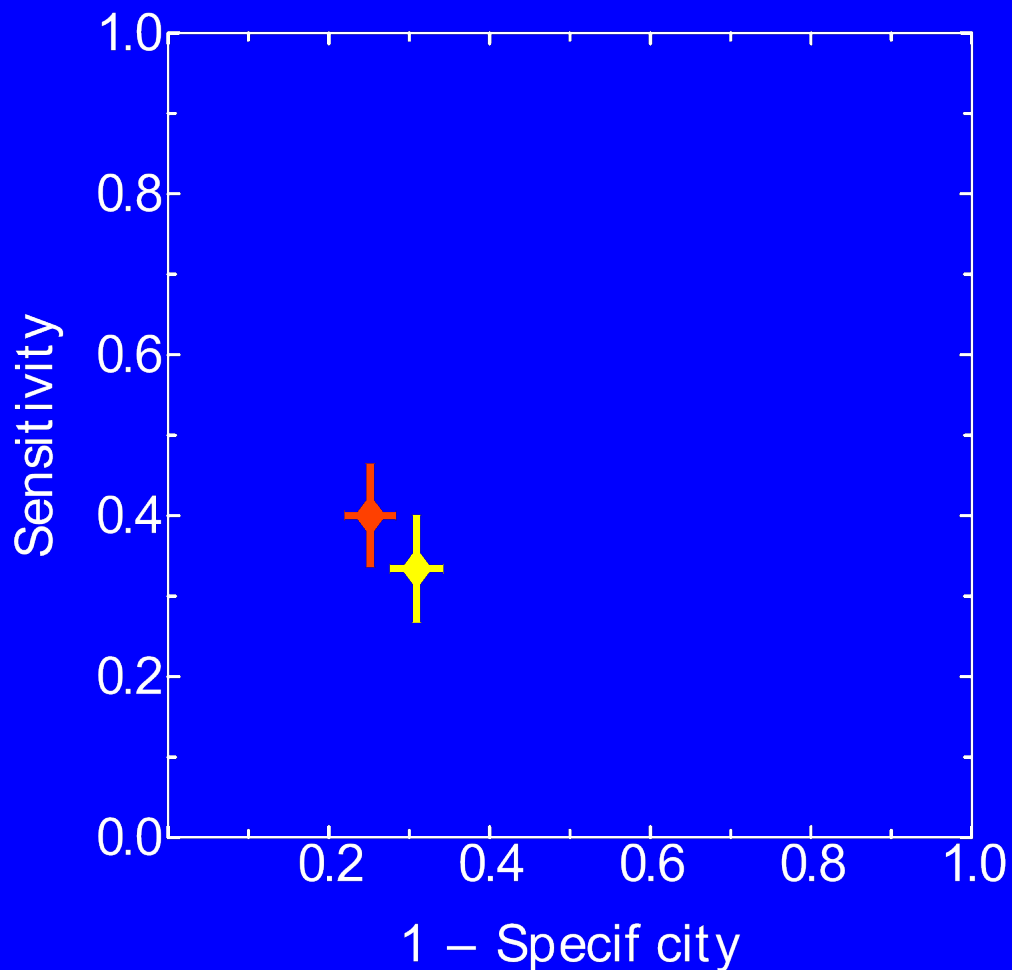
32 Readers, 140 Cases, Lesion Localization (15-mm)



	Sensitivity	1-Specificity
<b>FFDM</b>	<b>33 ± 7%</b>	<b>31 ± 3%</b>
<b>FFDM+SoftVue</b>	<b>40 ± 6%</b>	<b>25 ± 3%</b>
<b>95% CI of <math>\Delta</math></b>	<b>(-1%, 14%)</b>	<b>(-11%, -0.3%)</b>

# Sensitivity, Specificity: Short-term Follow-up or Biopsy

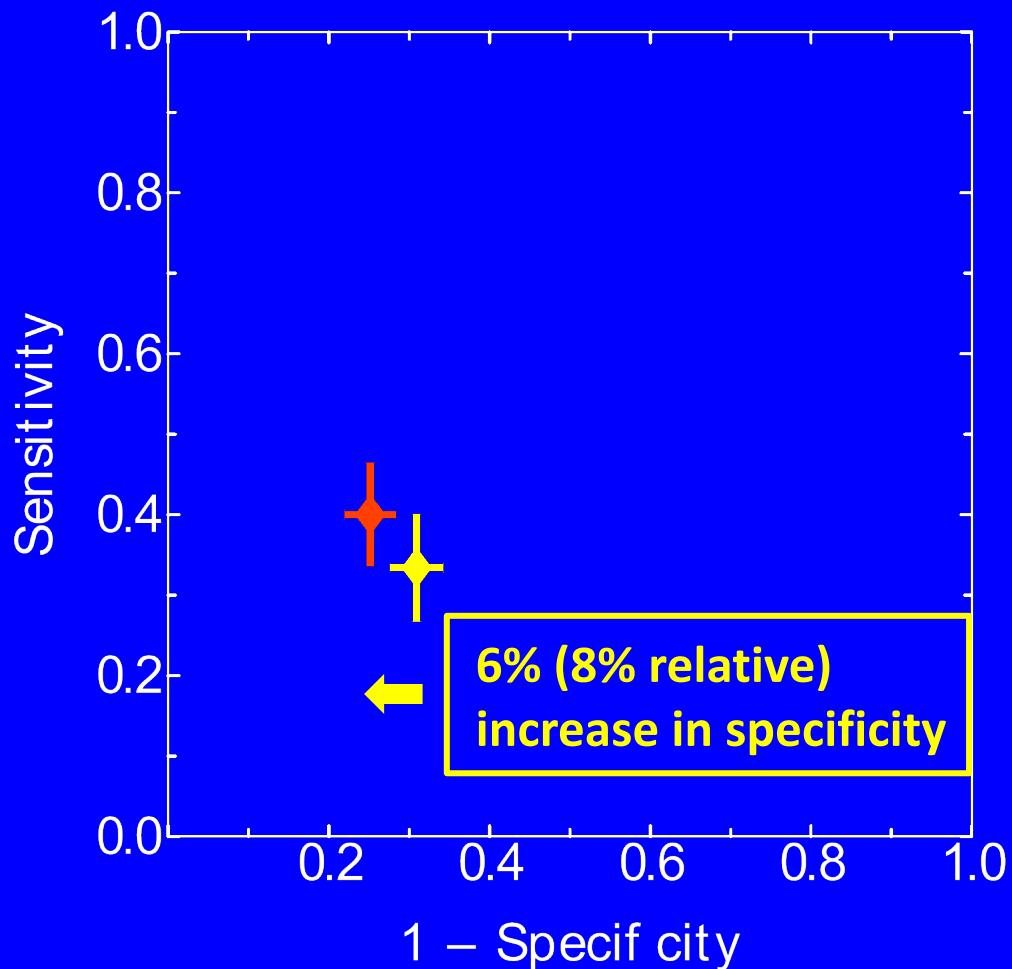
32 Readers, 140 Cases, Lesion Localization (15-mm)



	Sensitivity	1-Specificity
<b>FFDM</b>	<b>33 ± 7%</b>	<b>31 ± 3%</b>
<b>FFDM+SoftVue</b>	<b>40 ± 6%</b>	<b>25 ± 3%</b>
<b>95% CI of <math>\Delta</math></b>	<b>(-1%, 14%)</b>	<b>(-11%, -0.3%)</b>

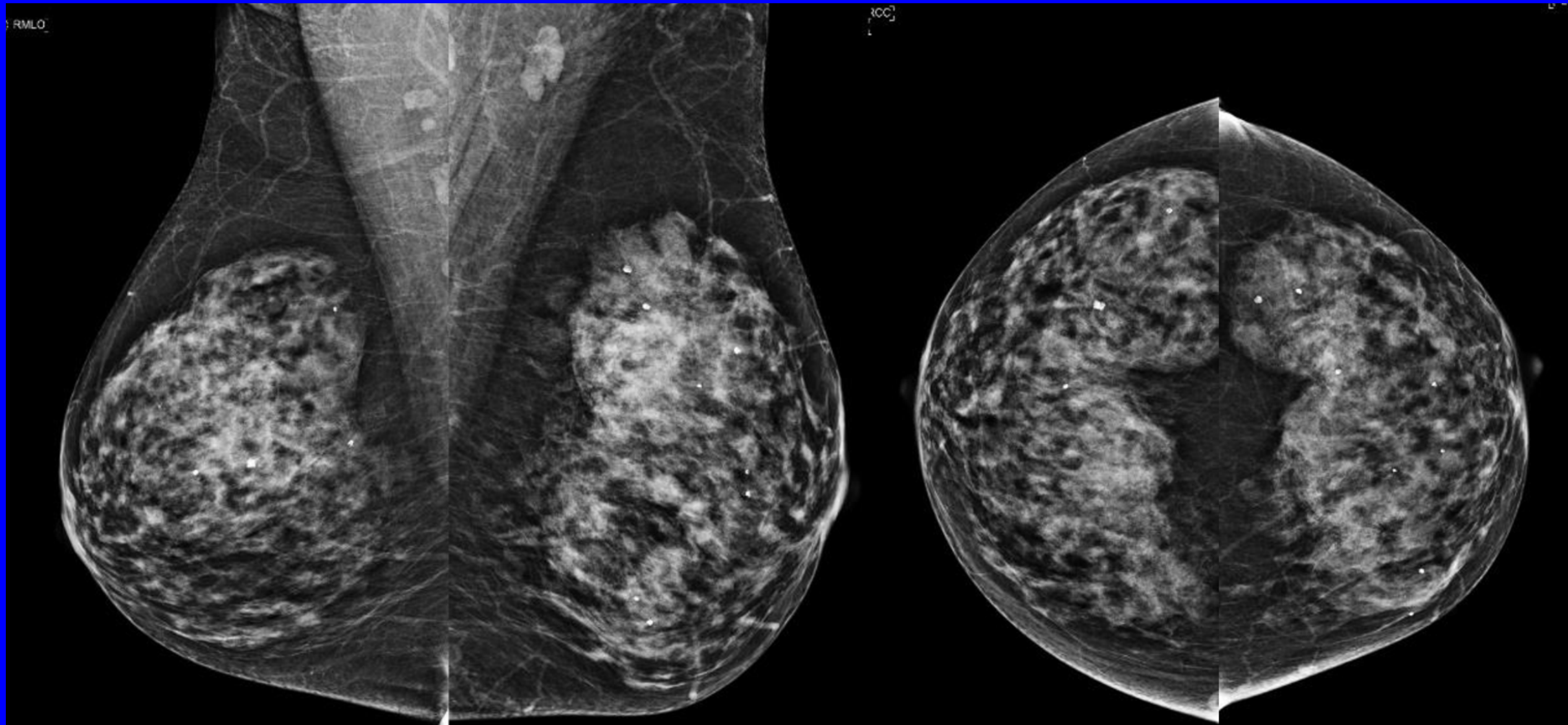
# Sensitivity, Specificity: Short-term Follow-up or Biopsy

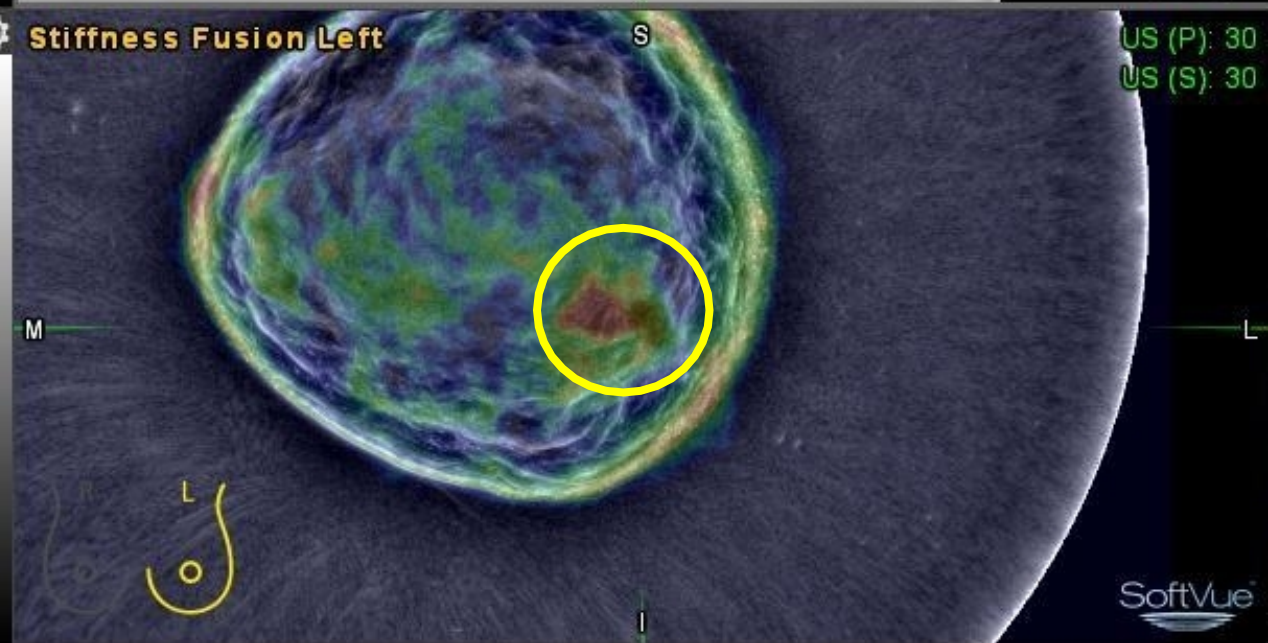
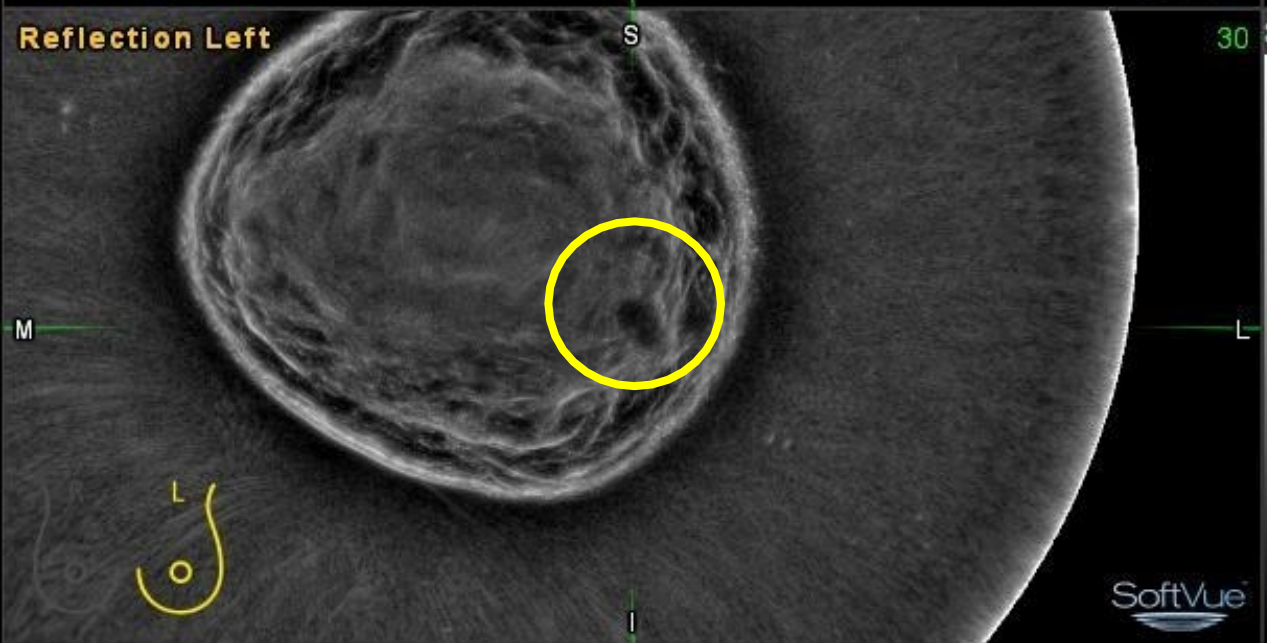
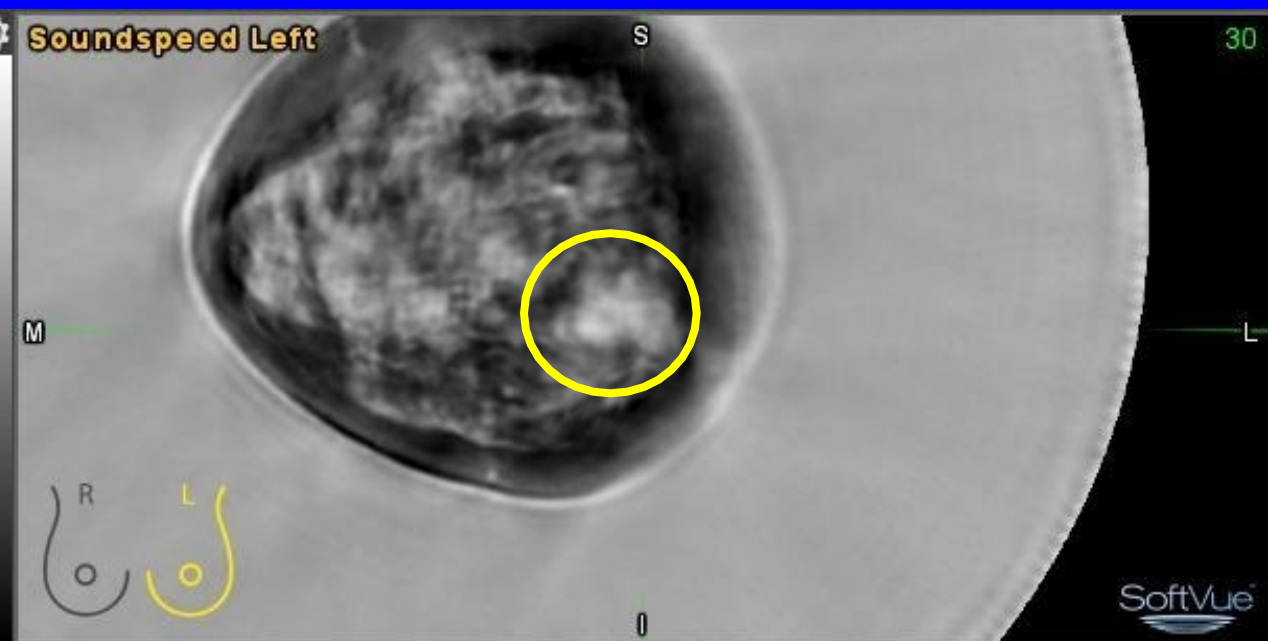
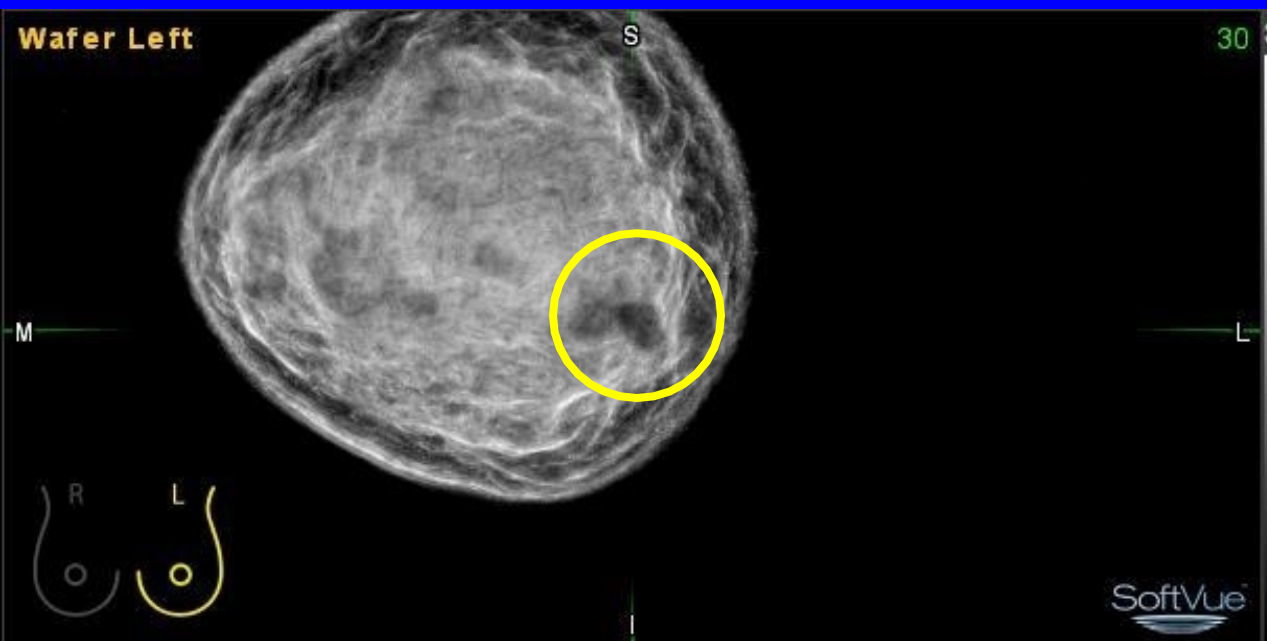
32 Readers, 140 Cases, Lesion Localization (15-mm)



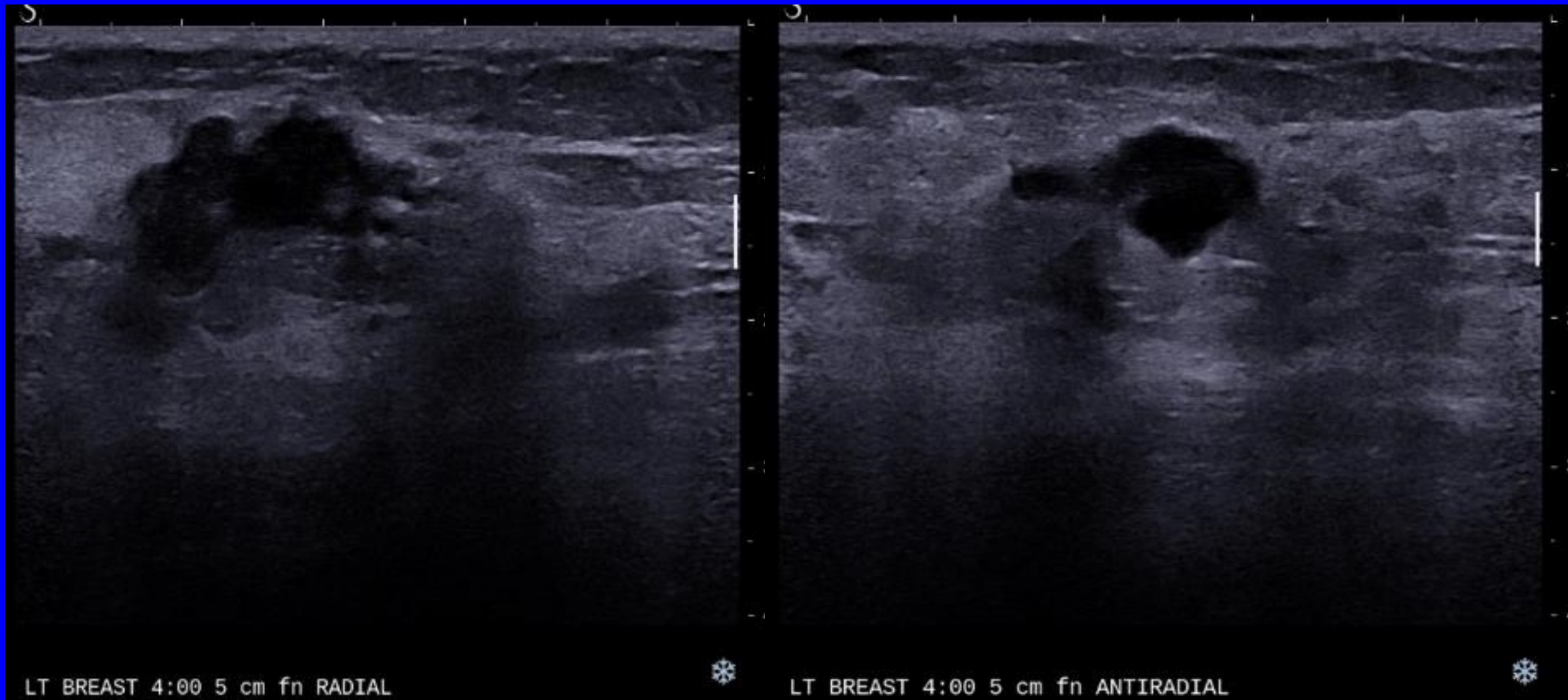
	Sensitivity	1-Specificity
<b>FFDM</b>	<b>33 ± 7%</b>	<b>31 ± 3%</b>
<b>FFDM+SoftVue</b>	<b>40 ± 6%</b>	<b>25 ± 3%</b>
<b>95% CI of <math>\Delta</math></b>	<b>(-1%, 14%)</b>	<b>(-11%, -0.3%)</b>

# BI-RADS Density C, Negative FFDM

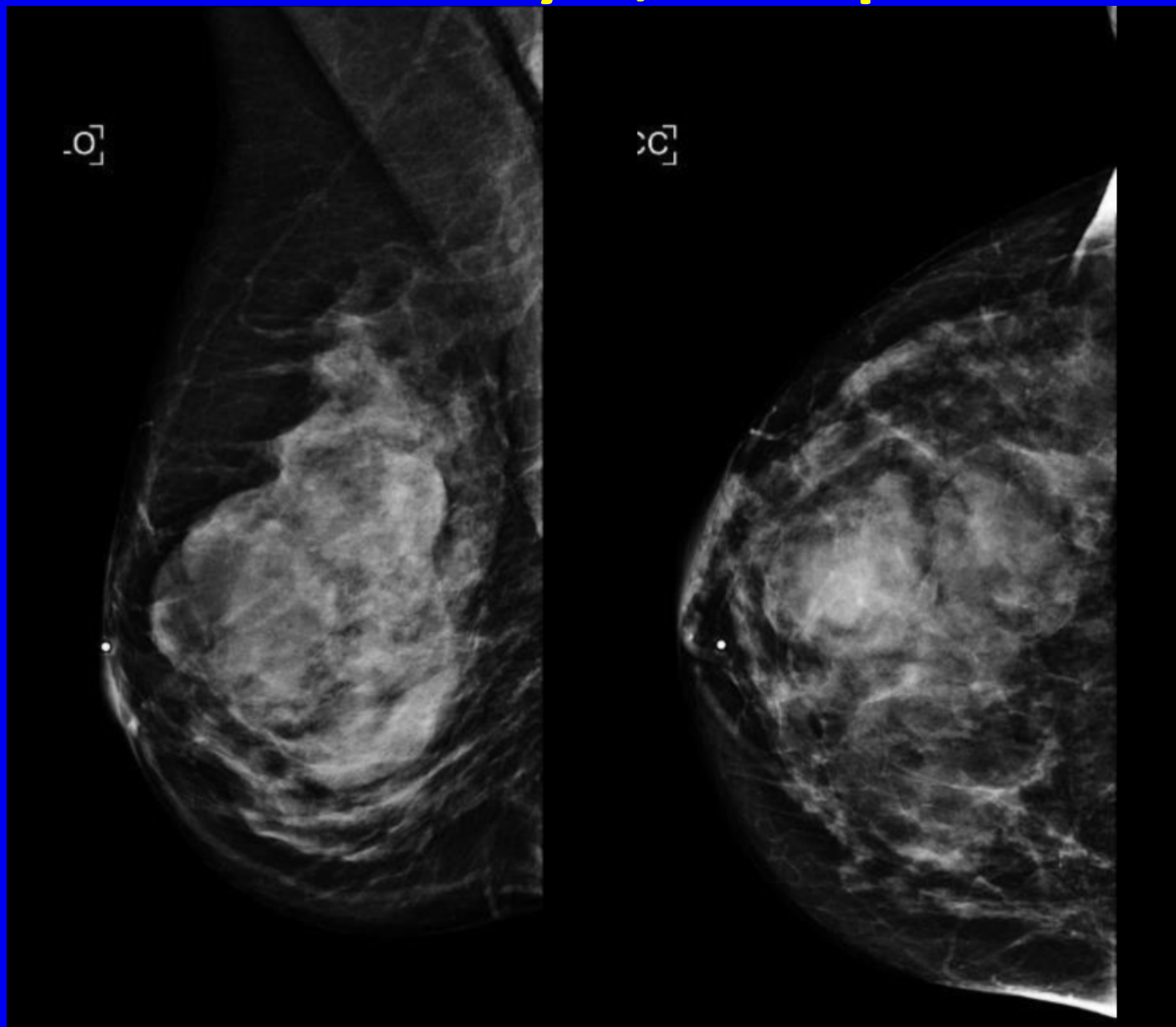




# Invasive Ductal Carcinoma



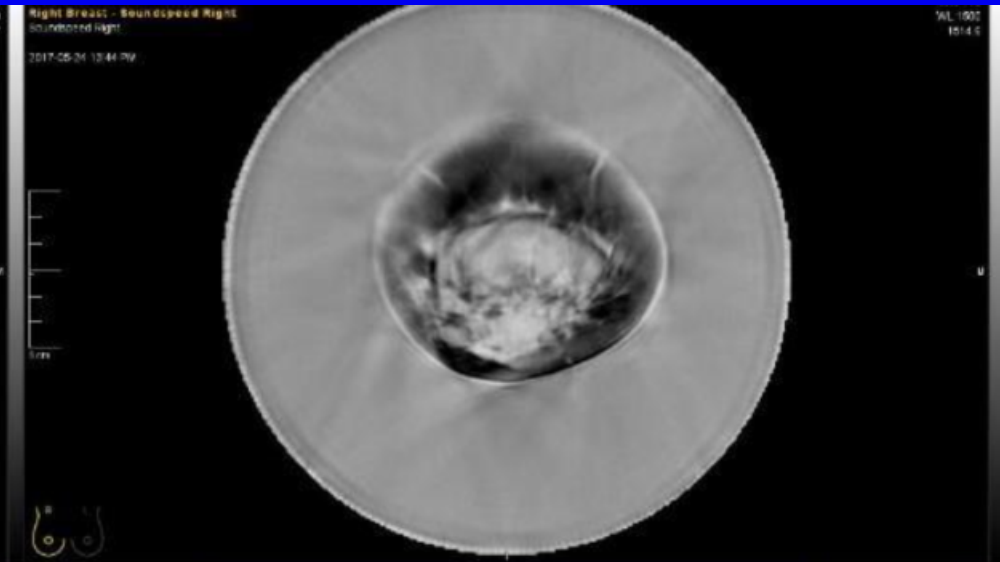
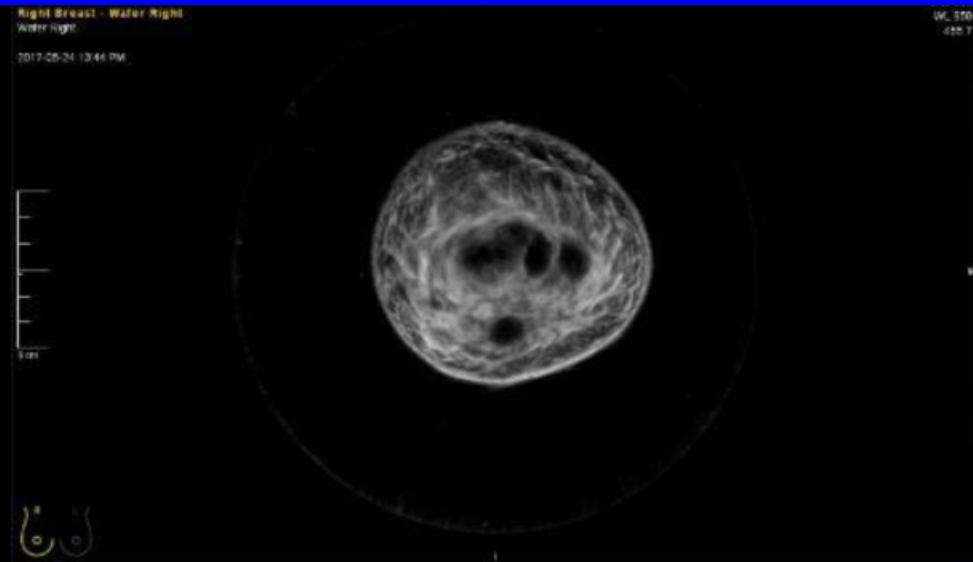
# BI-RADS Density D, Multiple Masses





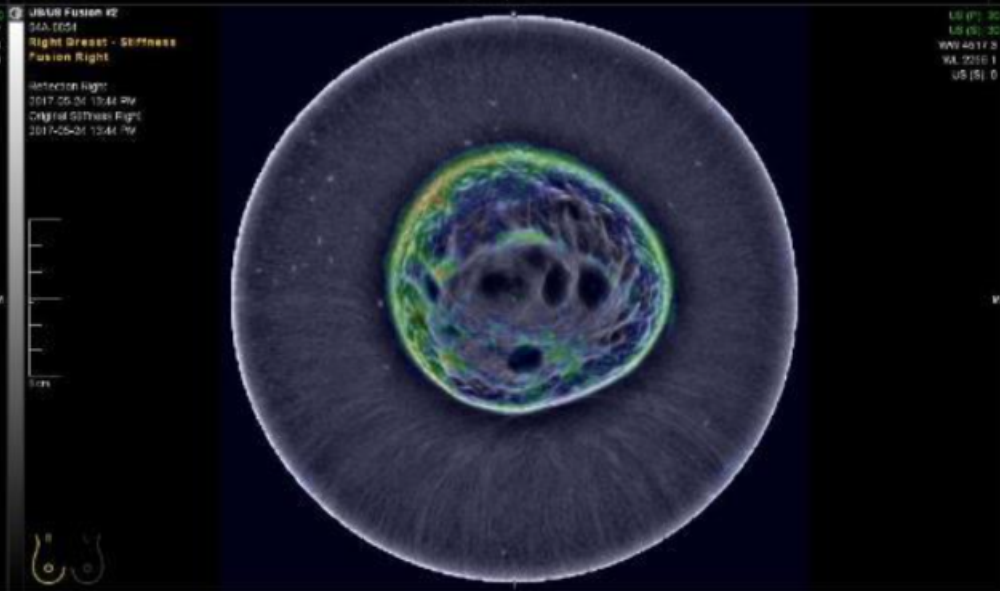
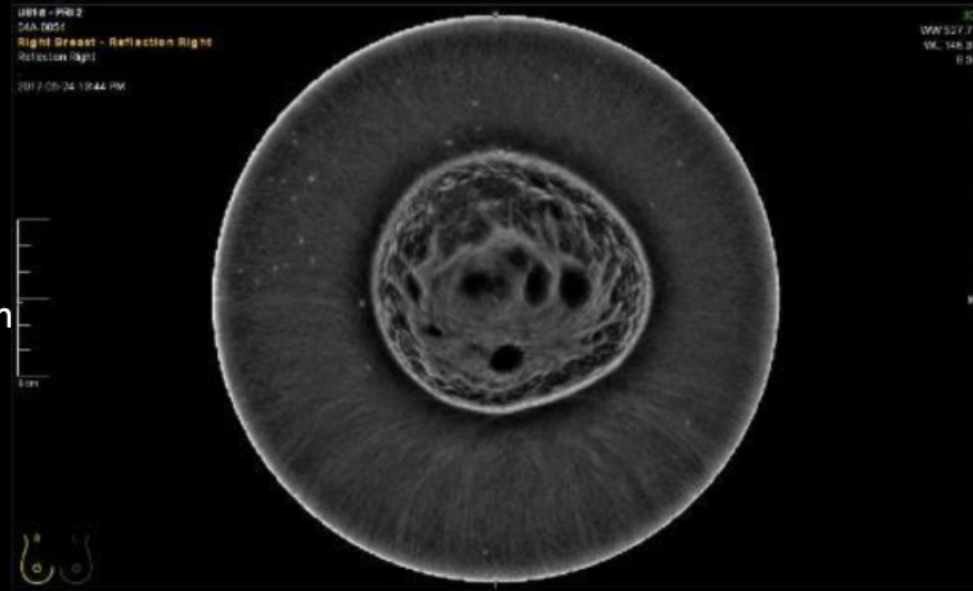
RT  
Slice #16

Wafer



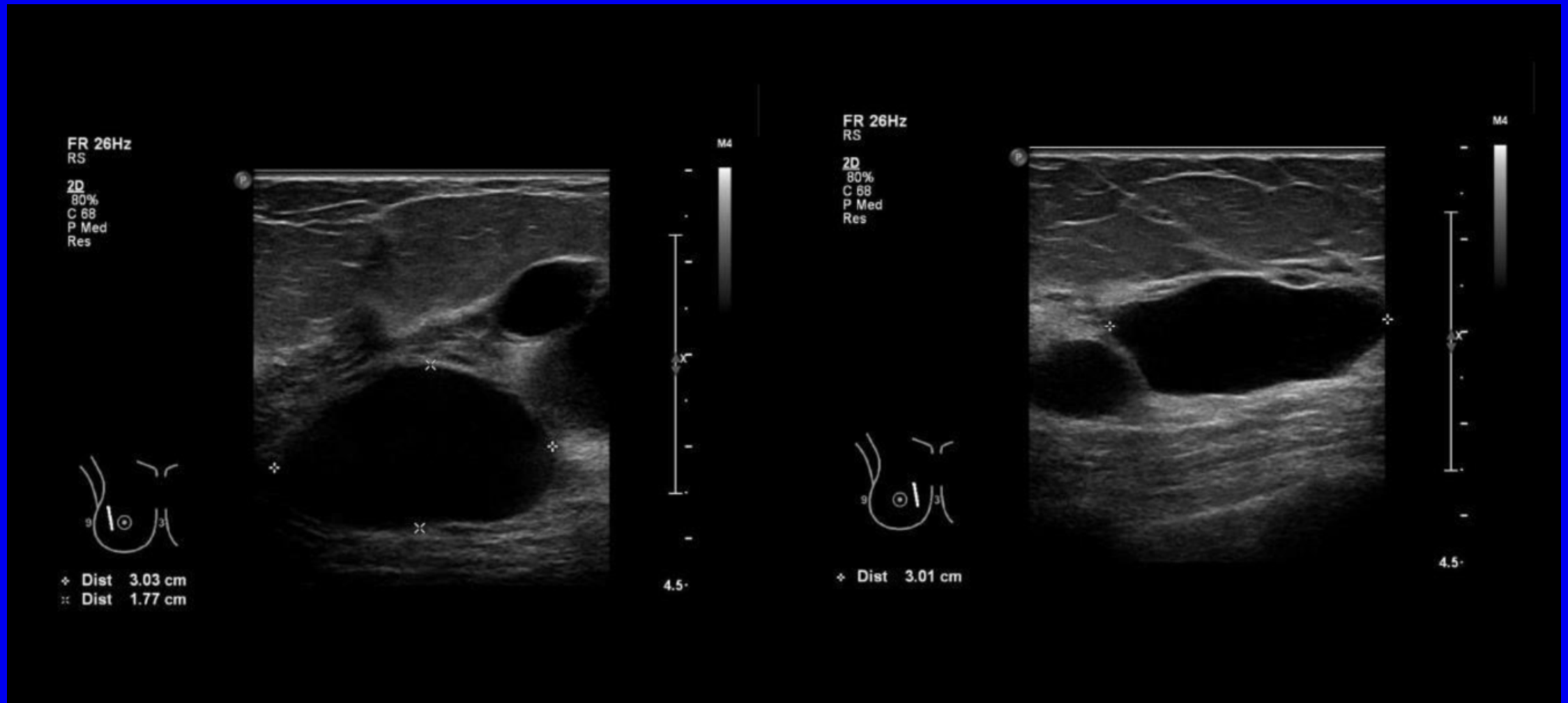Sound Speed

Reflection



Stiffness  
Fusion

# Multiple Cysts on HHUS



## Conclusion

**Adding SoftVue to screening FFDM for dense breast can improve cancer detection without decreasing specificity.**