

# Ultrasound Tomography of Breast Tissue

Nebojsa Duric<sup>\*a,b</sup>, Peter Littrup<sup>b</sup>, Earle Holsapple<sup>b</sup>, Alex Babkin<sup>c</sup>, Robert Duncan<sup>c</sup>, Arkady Kalinin<sup>c</sup>, Roman Pevzner<sup>c</sup> and Michael Tokarev<sup>c</sup>

<sup>a</sup>Department of Physics and Astronomy, University of New Mexico, Albuquerque, NM 87131

<sup>b</sup>Karmanos Cancer Institute, 110 East Warren Ave, Detroit MI 48201

<sup>c</sup>Groupvelocity, LLC; 801 University Blvd., Suite 104A, Albuquerque, NM 87106

## ABSTRACT

The Karmanos Cancer Institute is developing an ultrasound device for measuring and imaging acoustic parameters of human tissue. This paper discusses the experimental results relating to tomographic reconstructions of phantoms and tissue. The specimens were scanned by the prototype scanner at a frequency of 1.5 MHz using 2 microsecond pulses. The receivers and transmitters were positioned along a ring trajectory having a diameter of 20 cm. The ring plane is translated in the vertical direction allowing for 3-D reconstructions from stacked 2-D planes of data. All ultrasound scans were performed at 10 millimeter slice thickness to generate multiple tomographic images.

In a previous SPIE paper we presented preliminary results of ultrasound tomographic reconstruction of formalin-fixed breast tissue. We now present new results from data acquired with the scanner. Images were constructed using both reflection-based and transmission based algorithms. The resulting images demonstrate the ability to detect sub-mm features and to measure acoustic properties such as sound speed. Comparison with conventional ultrasound indicates the potential for better margin definition and acoustic characterization of tissue.

**Keywords:** ultrasound imaging, tissue characterization, acoustic parameters, breast cancer.

## 1. INTRODUCTION

The Karmanos Cancer Institute (KCI) is developing an ultrasound (US) device for measuring and imaging acoustic parameters of human tissue. Improved tissue characterization could result in a reduction of the estimated one million benign biopsies performed each year in the United States<sup>1</sup>, costing up to several billion dollars<sup>2</sup>. Most breast calcifications are benign and comprise ~ 80% of stereotactic biopsies guided by mammography<sup>3</sup>. Ultrasound has the capability of finding some groups of calcifications<sup>4,6</sup>, but further improvements in resolution should also address tissue characterization to define the soft tissue filling of ducts by DCIS. In this manner, US tomography may be able to more accurately identify the malignant calcifications associated with progression of DCIS or early cancers. Currently, high-resolution US images of the breast are performed in the reflection mode (B-mode) at relatively high frequencies (roughly 5 – 15 MHz). Reconstruction of reflection ultrasound images relies upon acoustic impedance differences in the tissue and includes only direct backscatter of the ultrasound signal. Resolution and tissue contrast of current US continues to improve with denser transducer arrays and better image processing. However, direct tissue characterization and reliable detection of sub-mm structures (i.e., microcalcifications) in a highly scattering medium such as breast tissue remain elusive.

The KCI device has been developed to the engineering prototype stage and has been used to perform a variety of experiments. The experiments are described in previous papers<sup>7,8</sup>. The data obtained from these experiments have been

\*duric@unm.edu; phone: 1 505 277 5238; fax: 1 505 277 1520

used to construct tomographic ultrasound images. In this paper, we present a number of US images of a cadaveric breast, using data obtained with the experimental ring scanner. The images are compared with X ray CT tomographs of the same sample in order to evaluate the “truth” of the observed structures.

Ultrasound tomography has the potential to improve US imaging in three fundamental ways. First, by utilizing a large variety of views, US tomography has the potential to produce better image quality through the reduction of speckle and increased signal to noise ratios. Compound imaging (e.g., SonoCT, Philips) of even a small number of views has already led to dramatic improvements in image quality of standard reflection US<sup>9,10</sup>. Second, by using distributed arrays of receiving elements, it is possible to capture much of the US energy that is scattered within the tissue. Capturing the scattered US and accounting for its trajectories has the potential to further improve the image quality by increasing the signal to noise ratio at each image pixel and increasing the spatial resolution<sup>8,10</sup>. Finally, another major benefit of US tomography is that it provides information about the acoustic properties of the insonified tissue<sup>8,11-14,17-18</sup>. By timing the arrival of the received pulses and noting changes in their amplitudes can lead to estimates of quantities such as sound speed and attenuation<sup>7,8,11-14</sup>.

## 2. MATERIALS AND METHODS

The initial technical goal of the KCI program was to achieve sub-millimeter resolution and quantitative tissue characterization using both reflection and transmission US. To that end KCI contracted with the Lawrence Livermore National Laboratory (LLNL) to build an engineering prototype capable of acquiring 3-D US data. The engineering prototype and some of the initial results are described in previous papers<sup>7,8</sup>. The associated image reconstructions are being used to test the feasibility of characterizing tissue, as described below.

### 2.1 The Data

Data were acquired by scanning a normal cadaveric breast placed in formalin and sealed in a 10-cm diameter, cylindrical container. The cadaveric breast was scanned by the KCI scanner at a frequency of 1.5 MHz using 2 microsecond pulses. The experimental setup is shown in figure 1. The relatively low frequency of 1.5 MHz was used in order to better penetrate the dehydrated, formalin-fixed breast. The receivers and transmitters were positioned along a ring trajectory having a diameter of 20 cm. A total of 1280 receiver positions and 320 transmitter positions were used, corresponding to  $\lambda/4$  and  $\lambda$  spacing, respectively. The target was placed at the center of the ring with the long axis of the cylinder oriented vertically relative to the plane of the ring. Each data set represents a 2-D slice through the phantom. The ring plane could be translated in the vertical direction allowing for 3-D reconstructions from stacked 2-D planes of data. The breast was also scanned with a clinical reflection ultrasound unit (GE Logiq 600) and a clinical X-Ray CT scanner (GE Lightspeed Quad detector array). The former was used for comparing image quality while the latter was used to establish the “truth” images. The CT scans were performed at 1.25 mm slice thickness. All US scans were performed at 10 millimeter slice thickness to generate multiple tomographic images per phantom.

### 2.2 The Algorithms

Acquiring the data is only the first step in tissue characterization. Producing quantitative ultrasound images requires the ability to accurately model the physics of US pulse propagation in tissue. In this study, the acoustic properties of sound speed, attenuation and reflectivity were determined and imaged using a family of algorithms. The algorithms are grouped into two basic types, according to whether they use the recorded back-scattered field or the forward-scattered field to construct the images. The former are referred to as *reflection algorithms* while the latter are termed *transmission algorithms*. The relevant geometries are shown schematically in figure 2.

#### Reflection Algorithms:

An algorithm based on Kirchoff migration was developed in order to construct reflection images from the backscattered acoustic field. An extension of reflection mode imaging, or so-called “B-scans” currently used in medical ultrasound, this algorithm produces images that highlight scattering sources in the insonified object. It assumes the wave scattering is isotropic and sound speed in the medium is known or calculable. A linearizing assumption is made that acoustic

energy scattered by each individual point object does not scatter off other point scatterers. This assumption of ignoring multiple scattering allows one to formulate the imaging solution for a single point scatterer independent of all other point scatterers. Then, the solution involving all point scatterers becomes the linear superposition of the result from each individual point scatterer. The scattered signal from a given point in the object is sampled around the aperture formed by the revolving receive transducer. Assuming the point scatterers isotropically, it effectively becomes a secondary point source. Thus, the goal of the imaging method is to determine the location of the point source given the data collected around the aperture.

#### Transmission Algorithms:

The simplest implementation of an image reconstruction algorithm ignores scattering and assumes that the ultrasound pulses travel in straight lines. The pulses that reach the receive transducers through forward scattering are used to create tomographic reconstructions in a manner directly analogous to X-ray tomography. Sound speed information is extracted on the basis of arrival time differences. Attenuation is determined on the basis of the strength (amplitude) of the arriving signal relative to the transmitted signal. Early results from these algorithms are described in previous papers<sup>7,8</sup>.

### 3. RESULTS

We now describe and discuss the images constructed with the above algorithms using data acquired with the KCI scanner. Figure 3 shows a mosaic of reflection US images at 1.5 MHz and X-ray CT images. The former were generated by using the migration-based algorithms, using scanner data obtained from four adjacent slices, each separated by 5 mm. Each resultant tomograph has an effective thickness of 10 mm. The corresponding X-ray CT slices were produced with an effective thickness of 1.25 mm. The normal breast specimen shows predominantly fatty tissue with thin but prominent internal fibrous bands. The US image shows the overall specimen configuration with excellent morphologic comparison to the CT scan. There is also no loss of signal or resolution seen in the near or far field. Despite the low frequency of the US tomography image, the fine architectural detail of internal fibrous bands is similar to the CT image (the latter was made at a thinner slice thickness and resultant high radiation exposure).

In addition to the reflection images, images of sound speed and attenuation were also made. The reflection and transmission data were fused to produce overlays of reflection images on sound-speed images. The overlays are shown in Figure 4 for two slices. The corresponding X-ray images are shown for reference. Tissue characterization of ultrasound parameters was not directly correlated with any histologic section, but the background sound speed pattern matches the overall fatty appearance on the X-ray CT scan. The grey scale represents varying speeds. The whitest portions represent a sound speed of about 1400 m/s. The darkest regions have speeds of about 1500 m/s.

### 4. DISCUSSION

The feasibility of sub-millimeter resolution ultrasound with potential tissue characterization by sound parameters has been demonstrated for the engineering prototype phase of the KCI program. These goals were confirmed in the complex scattering medium of the cadaveric human breast tissue. Similar, or even better, in-vivo performance is anticipated because of the high water content and lower attenuation in living tissue. The potential benefits for clinical breast imaging are improved tumor margin visualization and characterization. We now discuss the potential for characterization using morphology based on reflectivity, sound speed and attenuation.

*Reflectivity:* Breast tissue characterization by current reflection US may be best represented by the success of the 'Stavros/Colorado' criteria for mass margin evaluation<sup>15</sup>. The 98% accuracy obtained for defining a benign mass rested upon the criterion of an ovoid mass with well-defined margins. This was sufficient for ATL, Inc. to obtain separate Food and Drug Administration approval for characterizing benign breast masses with their high-resolution transducer in 1996<sup>16</sup>. Compound imaging<sup>9</sup> produces a single averaged image from 3-9 single angled scans, reducing speckle, clutter and ultrasound artifacts. Mass margins are thus better identified<sup>10</sup>. However, little clinical progress has been noted for additional US tissue characterization to improve breast tissue diagnosis. The US reflection images shown here (Figure 3) suggest that mass margin definition may be greatly expanded when evaluated using multiple views, and perhaps in 3

dimensions. Identification of clear mass margins from US tomography therefore does not suffer from the need for tumor capsules<sup>5,15</sup> to be discretely identified as specular reflectors, nor from incomplete lateral margins from diffraction artifacts. The possibility for three-dimensional evaluation of all aspects of tumor mass may hold great promise for improved tissue characterization by simple morphology.

*Sound Speed:* Images of sound speed are shown in Figures 4. The sound speed images of the cadaveric breast show well-defined variations in the sound speed, ranging from 1400 m/s to over 1500 m/s. This range of sound speed is consistent with known variations in sound speed for the breast. The lower range represents fatty tissue while the higher range represents ducts and muscle tissue. Inspection of figure 4 shows that the fibrous bands are embedded within tissue with sound speed lower than water. Sound speeds in the medium range from 1400 to 1450 m/s, below that of water. Comparison with data from the visible woman project suggests that, on the basis of sound speed alone, the medium is that of fatty breast tissue. *A priori* knowledge of the excised breast confirms that this specimen is a fatty breast. Some enhancement of the sound speed in regions where the fibrous bands are concentrated is also evident. Such an enhancement is expected since fibrous tissue and ductal tissues have sound speed higher than fat.

The greatest potential benefit of tissue characterization is the ability to discriminate accurately between cancerous and non-cancerous tissue. It is unlikely that any one acoustic parameter will do the job. The most likely path to successful tumor differentiation will combine multiple acoustic parameters<sup>17</sup>. The combined information of reflection and sound speed (when compared to the X-ray CT scan) increases the characterization of the breast tissue by identifying the fatty tissues and the fibrous bands. The use of multi-parameter characterization (data fusion) was discussed in a separate paper<sup>18</sup>.

## 5. CONCLUSIONS AND FUTURE WORK

It has been shown that the combination of angular diversity (multiple views) and good image reconstruction algorithms can yield tomographic US images capable of showing sub-millimeter-sized features in a highly scattering medium, as well as having the potential to characterize breast tissue. Fusion of reflectivity and sound speed data holds great promise for tissue characterization in patient trials. Future work will concentrate on reconstructions of acoustic attenuation to complement the use of sound speed and reflectivity in a multi-parameter study of tissue characterization.

## 6. ACKNOWLEDGMENTS

Funding for this project was provided by philanthropic support of the Karmanos Cancer Institute.

## REFERENCES

1. Liberman L. Clinical management issues in percutaneous core breast biopsy. *Radiol Clin North Am.* 2000; 38:791-807.
2. Secker-Walker RH, Vacek PM, Hooper GJ, Plante DA, Detsky AS. Screening for breast cancer: time, travel, and out-of-pocket expenses. *J Natl Cancer Inst* 1999, 91:702-8.
3. Makoske T, Preletz R, Riley L, Fogarty K, Swank M, Cochrane P, Blisard D. Long-term outcomes of stereotactic breast biopsies. *Am Surg.* 2000, 66:1104-8.
4. Cleverley JR, Jackson AR, Bateman AC. Pre-operative localization of breast microcalcification using high-frequency ultrasound. *Clin Radiol.* 1997; 52:924-6.
5. Skaane P. Ultrasonography as adjunct to mammography in the evaluation of breast tumors. *Acta Radiol Suppl.* 1999; 420:1-47.
6. Teh WL, Wilson AR, Evans AJ, Burrell H, Pinder SE, Ellis IO. Ultrasound guided core biopsy of suspicious mammographic calcifications using high frequency and power Doppler ultrasound. *Clin Radiol.* 2000; 55:390-4.
7. Littrup, P. et al. Computerized Ultrasound Risk Evaluation (CURE) System: Development of Combined Transmission and Reflection Ultrasound with New Reconstruction Algorithms for Breast Imaging. *Acoustical Imaging, Volume 26, Kluwer Academic Plenum Publishers, 2002: 175-182.*
8. Littrup PJ, Duric N, Leach Jr. RR, Azevedo SG, Candy JV, Moore T, Chambers DH, Mast JE and Holsapple ET. *Characterizing tissue with acoustic parameters derived from ultrasound data.* Proceedings of the SPIE: Medical Imaging 2002; San Diego, California; Feb. 23-28, 2002. Ultrasonic Imaging and Signal Processing – Paper 4687-43.
9. Entekin RR, Porter BA, Sillesen HH, Wong AD, Cooperberg PL, Fix CH. Real-time spatial compound imaging application to breast, vascular, and musculoskeletal ultrasound. *Semin Ultrasound CT MR* 2001 Feb;22(1):50-64
10. Shapiro RS, Simpson WL, Rausch DL, Yeh HC. Compound spatial sonography of the thyroid gland: evaluation of freedom from artifacts and of nodule conspicuity. *AJR Am J Roentgenol* 2001 Nov;177(5):1195-8
11. A. J. Devaney. A filtered backpropagation algorithm for diffraction tomography. *Ultrasonic Imaging, 4(4):336-350, October 1982.*
12. André MP, Janee HS, Martin PJ, Otto GP, Spivey BA, Palmer DA. High-speed data acquisition in a diffraction tomography system employing large-scale toroidal arrays. *International Journal of Imaging Systems and Technology* 1997; 8:137-147.
13. S. A. Johnson and M. L. Tracy. Inverse scattering solutions by a sinc basis, multiple source, moment method. Part I: Theory, *Ultrasonic Imaging, 5:361-375, 1983.*
14. Natterer, F. A Propagation-Backpropagation Method for Ultrasound Tomography, *Inverse Problems* 11, 1225-1232, 1995.
15. Stavros AT, Thickman D, Rapp CL, Dennis MA, Parker SH, Sisney GA. Solid breast nodules: use of sonography to distinguish between benign and malignant lesions. *Radiology.* 1995;196:123-34.
16. 61 Federal Register 60712-60713 (1996). (<http://www.rsna.org/REG/research/regulatory/wfprfcexamples.html>).
17. Schreiman JS, Gisvold JJ, Greenleaf JF, Bahn RC. Ultrasound transmission computed tomography of the breast. *Radiology* 1984; 150:523-30.
18. Duric N, Littrup PJ, Leach Jr. RR, Azevedo SG, Candy JV, Moore T, Chambers DH, J. Mast JE and Holsapple ET. *Using Data Fusion to Characterize Breast Tissue.* Proceedings of the SPIE: Medical Imaging 2002; San Diego, California; Feb. 23-28, 2002. Ultrasonic Imaging and Signal Processing – Paper 4687-39.

## FIGURES




Figure 1: The experimental setup, showing the engineering scanner, the water tank and the cadaveric breast.

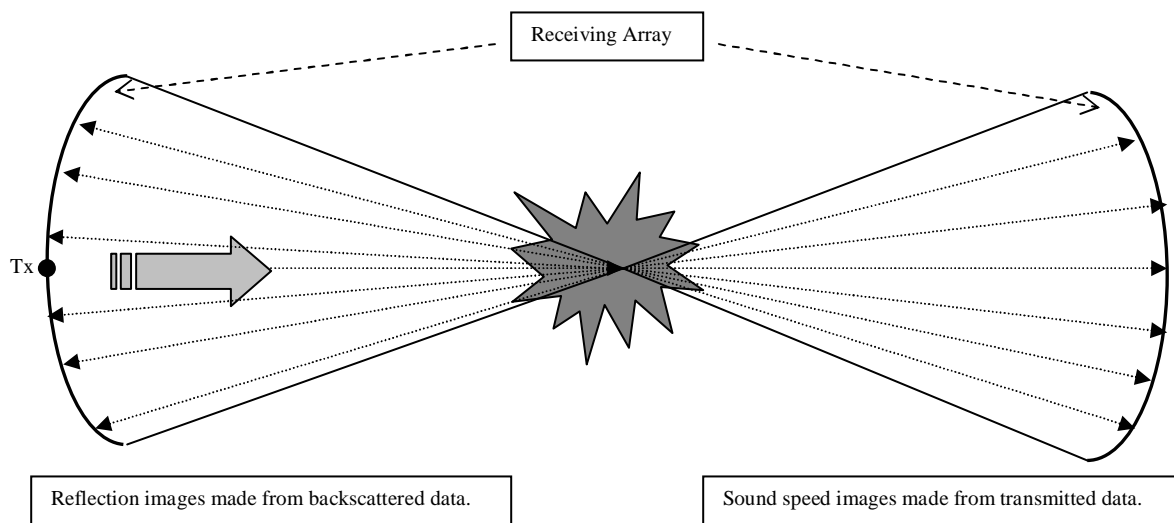


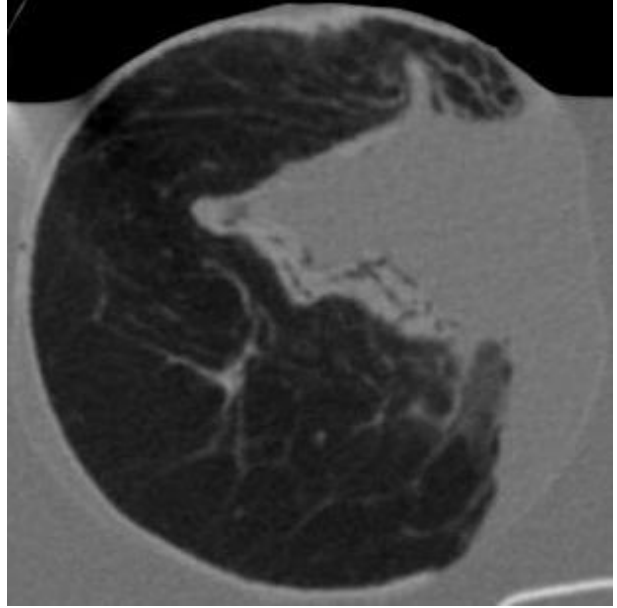


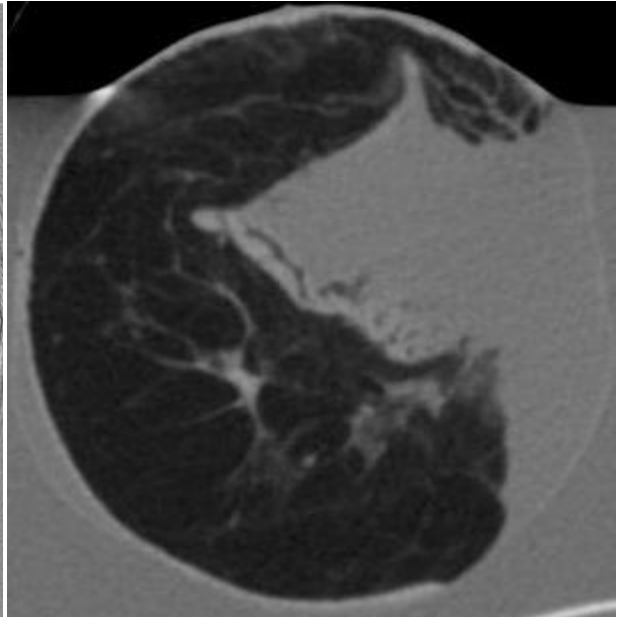
Figure 2: Schematic showing the data used to create reflection and transmission images.

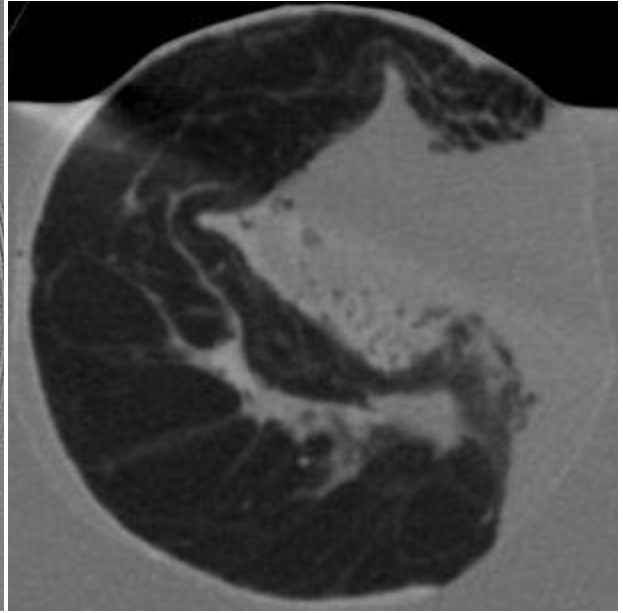



Slice 1

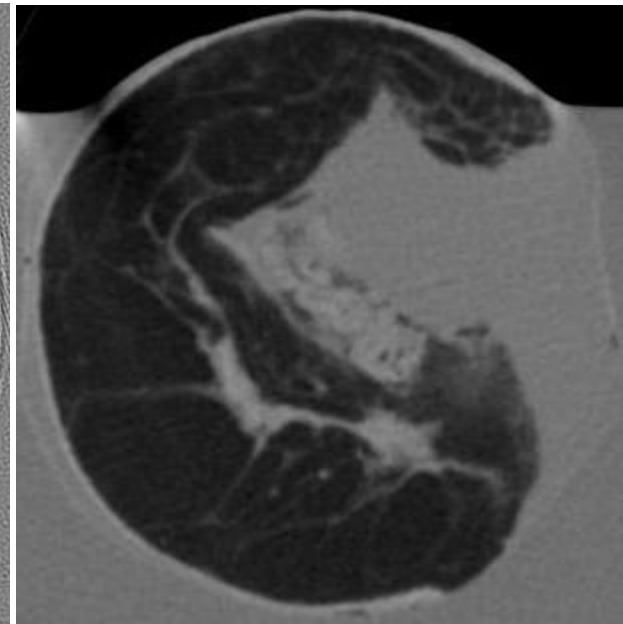



Slice 2





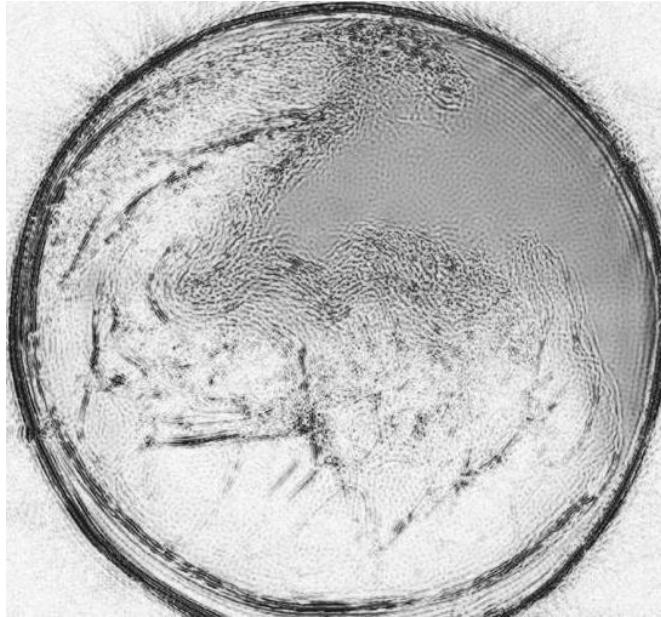
Slice 3



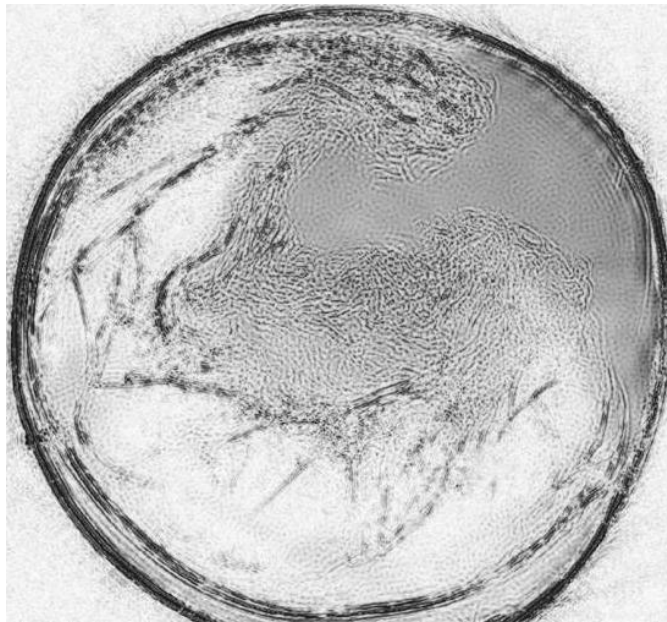
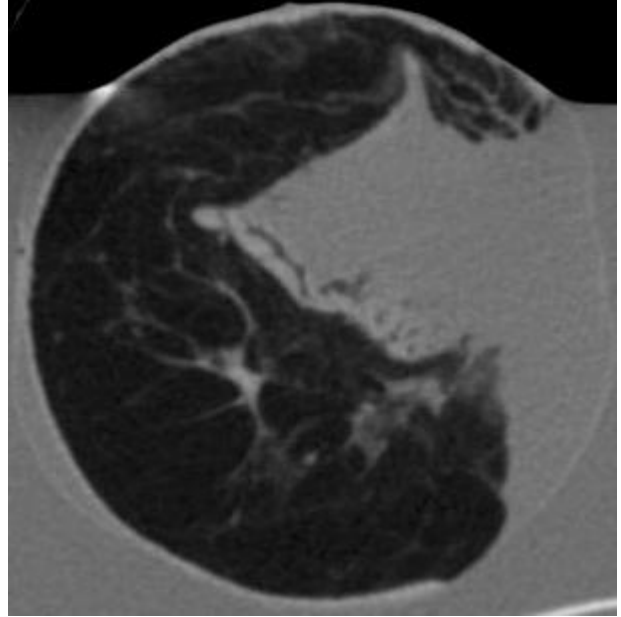
Slice 4

Figure 3. Images are shown for four adjacent cross sections of the cadaveric breast. The images on the left are US reflection images made using a migration-based reconstruction algorithm. The images on the right were obtained from X-ray CT scans.





Slice 2



Slice 4

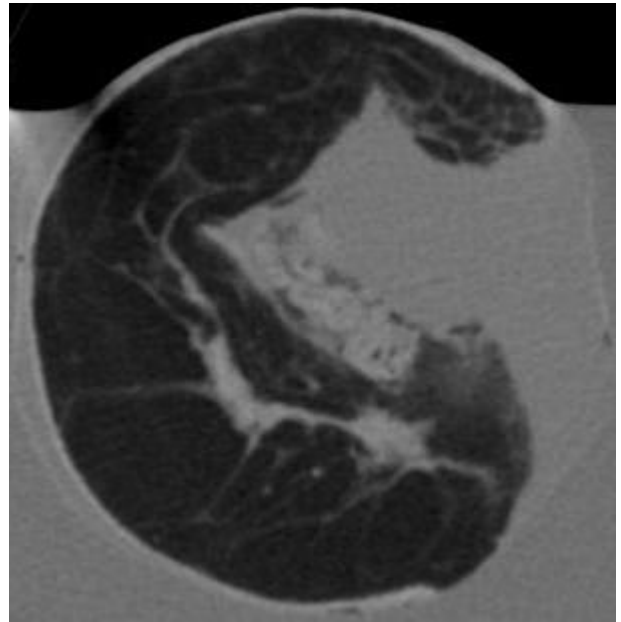


Figure 4. Examples of data fusion. The images on the left represent a superposition of reflection US images superimposed on images of sound speed. The corresponding X-ray CT scans are shown on the right.